

Original Research Article

# Histopathological study of bone lesions - A review of 102 cases

Dimpal Modi<sup>1\*</sup>, Gunvanti B. Rathod<sup>2</sup>, K. N. Delwadia<sup>3</sup>, H. M. Goswami<sup>4</sup>


<sup>1</sup>Tutor, Pathology Department, GMERS Medical College, Himmatnagar, Gujarat, India

<sup>2</sup>Assistant Professor, Pathology Department, GMERS Medical College, Himmatnagar, Gujarat, India

<sup>3</sup>Additional Professor, Pathology Department, BJ Medical College, Ahmedabad, Gujarat, India

<sup>4</sup>Professor and Head, Pathology Department, BJ Medical College, Ahmedabad, Gujarat, India

\*Corresponding author email: [dr.dimpal17@gmail.com](mailto:dr.dimpal17@gmail.com)

	International Archives of Integrated Medicine, Vol. 3, Issue 4, April, 2016.	
	Copy right © 2016, IAIM, All Rights Reserved.	
	Available online at <a href="http://iaimjournal.com/">http://iaimjournal.com/</a>	
	ISSN: 2394-0026 (P)	ISSN: 2394-0034 (O)
	Received on: 01-02-2016	Accepted on: 02-03-2016
	Source of support: Nil	Conflict of interest: None declared.
<b>How to cite this article:</b> Modi D, Rathod GB, Delwadia KN, Goswami HM. Histopathological study of bone lesions - A review of 102 cases. IAIM, 2016; 3(4): 27-36.		

## Abstract

**Background:** A spectrum of pathological bone lesions can be presented in any form from inflammatory to neoplastic conditions. Diagnosis of all bone lesions is made by radiological modalities like plain X-ray, CT scan, MRI and bone scintigraphy.

**Aim and Objectives:** To study histopathological features of bone lesions and correlate them with age, site and type of lesions.

**Material and Methods:** The study was carried out at tertiary care center from April 2013 to November 2013. A total of 102 bone lesions were analyzed. Bone biopsy was performed after detailed clinical and radiological examination. After fixation, decalcification, processing and H&E staining, histopathological diagnosis was made.

**Results:** Out of all 102 cases, 44.11% bone lesions were found between 25-50 years with male predominance. The incidence of non neoplastic lesions was 74.5% and neoplastic lesions were 25.4%. Amongst neoplastic lesions, incidence of benign tumors was 17.64% and malignant tumors were 7.8%. The Tuberculous Osteomyelitis was most common non neoplastic lesion while giant cell tumor and osteochondroma were common among benign tumors and osteosarcoma and Secondary metastasis were common among malignant bone tumors.

**Conclusion:** Though Bone tumors are less common, if viewed in perspective of clinico radiology and histopathology, correct diagnosis can be made.

## Key words

---

Bone lesions, Tuberculous osteomyelitis, Osteosarcoma.

## Introduction

---

A spectrum of pathological bone lesions can be presented in any form from inflammatory to neoplastic conditions. It is important to remember, however, that some benign processes such as osteomyelitis can mimic malignant tumours, and some malignant lesions such as metastases or myeloma, can mimic benign. It is difficult to determine radiologically with plain film imaging whether a bone lesion is benign or malignant [1].

Pyogenic osteomyelitis is an acute inflammatory condition most commonly caused by staphylococcus aureus. The osteolytic lesions of tuberculosis may closely mimic those due to multiple myeloma or secondary malignant deposits. Within benign lesions, the differential diagnosis includes simple bone cyst, aneurysmal bone cyst, osteochondroma (exostosis), enchondroma, giant cell tumor, fibrous dysplasia, osteoblastoma, chondroblastoma, non ossifying fibroma and brown tumor of the bone. Among the malignant tumors, the most common are primary bone tumors which include Chondrosarcoma, osteosarcoma, Ewing's sarcoma, Synovial sarcoma, multiple myeloma and adamantinoma [2, 3].

Primary bone cancer is much rarer than bone metastasis. Bone is the third most common site of metastatic disease. As far as secondary tumors are concerned primary sites like lung, kidney, thyroid, breast, gastrointestinal and melanomas produce mainly lytic lesion while others elicit mixed lytic and sclerotic reaction. Carcinomas are much more likely to metastasize to bone than sarcomas [4, 5].

The axial skeleton is seeded more than the appendicular skeleton, partly due to the persistence of red bone marrow in the former. The ribs, pelvis and spine are normally the first bones involved and distal bones are rarely

affected. Diagnosis of all bone lesions is made by radiological modalities like plain X-ray, CT scan, MRI and bone scintigraphy [6].

## Material and methods

---

The study was carried out at tertiary care centre. The criteria for the selection of patient were cases of radiologically apparent bone disease. Total 102 cases were selected and in all patients bone lesions were diagnosed radiologically.

In Orthopedic OPD, patients clinically presented with pain, swelling, non-healing fracture were included. Detailed history was taken which mainly included age, sex, place of residence, occupation, fever, weight loss, cough, haemoptysis or history suggestive of systemic involvement. All patients were subjected to thorough physical examination both, systemic and general examination.

In all patients X-ray of lesioned bone had been taken while CT scan and MRI were done according to the need and advice of orthopedic surgeon. Pathological investigation included routine CBC, ESR and Urine examination in all patients while sputum, body fluid examination, Serum Calcium and alkaline phosphatase were done in selected cases. Biopsy for histopathology was performed in all patients for the diagnosis of lesions. Biopsy was taken mainly by scrapping method, incision and excision method.

In laboratory soft tissue were fixed in 10 % formalin while for bone 3 to 5 mm thick sections were made and adequately fixed in 10% buffered formalin and then decalcification was achieved by placing the specimens in nitric acid. After that all tissue were processed by increasing concentrations of alcohol and paraffin, blocks were prepared. Sectioned were stained with haematoxylin and eosin. After that all slides were examined under microscope, the final diagnosis was made into inflammatory, benign and

malignant lesion accordingly. In selected cases IHC was performed to confirm histopathological findings.

## Results

Out of all 102 cases, (45 cases) 44.11% were found between 25-50 years with male predominance (68 cases) 66.7%. The incidence of non neoplastic lesions was (76 cases) 74.5% and neoplastic lesion was (26 cases) 25.4%. Amongst neoplastic lesions, incidence of benign tumors was (18 cases) 17.64% and malignant

tumor was (8 cases) 7.8%. The Tuberculous Osteomyelitis was most common non neoplastic lesion while giant cell tumor and osteochondroma were common among benign tumors and osteosarcoma and Secondary metastasis were common among malignant bone tumors (**Table – 1**).

Out of 102 patients, 68 (66.7%) were male and 34 (33.4%) were female (**Table – 2**). 45 cases (44.11%) were found between 25-50 years (**Table – 3**).

**Table - 1:** Proportion of different bone lesions.

Non Neoplastic	Neoplastic	
	Benign	Malignant
Acute/chronic inflammation-19	Osteoclastoma (Giant cell tumor )-4	Osteosarcoma-3
Koch's inflammation-20	Osteochondroma(Exostosis)-4	Chondrosarcoma-1
Acute/chronic osteomyelitis-15	Fibrous Histiocytoma-3	Synovial sarcoma-1
Rheumatoid arthritis-4	Pyogenic Granuloma-2	Metastasis-3
Osteoarthritis-2	Ossifying Fibroma-2	
Synovitis-10	Osteoma-1	
Others-6	Neurofibroma-1 Aneurysmal bone cyst-1	
<b>Total-76</b>	<b>Total Benign lesions-18</b>	<b>Total malignant lesions-8</b>

**Table - 2:** Gender distribution of the lesions of bone.

Bone lesions	Non neoplastic	Neoplastic		Total
		Benign	Malignant	
Male	52	11	5	<b>68</b>
Female	24	7	3	34
Total	76	18	8	102

**Table - 3:** Age wise distribution of the bone lesions.

Age (years)	Non neoplastic	Neoplastic		Total
		Benign	Malignant	
<25	24	3	1	28
25-50	31	10	4	45
>50	21	5	3	29
Total	76	18	8	102

Among various inflammatory lesions Koch's inflammation was more common followed by chronic inflammation followed by chronic osteomyelitis (**Table – 4**). Among various benign

lesions, Giant cell tumor and exostosis were most common (**Table – 5**). Among various malignant lesions, Osteosarcoma and metastasis were most common (**Table – 6**).

**Table - 4:** Distribution of various inflammatory lesions.

Various inflammatory lesions	No. of cases
Acute inflammation	5
Chronic inflammation	14
Koch's inflammation	20
Rheumatoid arthritis	4
Osteoarthritis	2
Acute osteomyelitis	3
Chronic osteomyelitis	12
Synovitis	10
Others	6
Total	76

**Table - 5:** Distribution of benign lesion.

Various Benign Lesions	No. of cases
Giant cell tumor (Osteoclastoma)	4
Osteochondroma (Exostosis)	4
Pyogenic granuloma	2
Fibrous histiocytoma	3
Ossifying fibroma	2
Osteoma	1
Neurofibroma	1
Aneurysmal bone cyst	1
Total	18

**Table - 6:** Distribution of various malignant lesions.

Various Malignant lesions	No. of cases
Osteosarcoma	3
Chondrosarcoma	1
Synovial sarcoma	1
Metastasis	3
Total	8

### Key histopathological features of bone lesions

#### Inflammatory lesions

Once in bone, the bacteria proliferate and induce acute inflammatory reaction. The entrapped bone undergoes necrosis within first 48 hours, and the bacteria and inflammation spread within shaft of bone and may percolate throughout the haversian systems to reach the periosteum.

Lifting of periosteum further impairs the blood supply to the affected region and both the

suppurative and ischemic injury may cause segmental bone necrosis, the dead piece of bone is known as sequestrum.

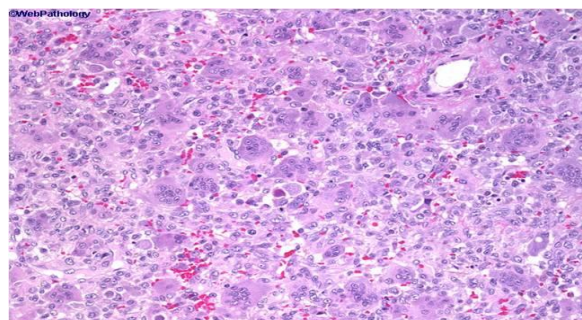
After the first week chronic inflammatory cells become more numerous and their release of cytokines stimulates osteoclastic bone resorption, in growth of fibrous tissue and deposition of new bone in periphery. When the newly deposited bone forms a sleeve of living tissue around the segment of devitalized infected bone, it is known as involucrum. Thus, in cases of pyogenic osteomyelitis large areas of necrosis, focal area of hemorrhage and acute inflammatory cells are found. In cases of tuberculous osteomyelitis, presence of epithelioid cells and caseation necrosis were inevitable. Few langhans giant cells and evident granuloma could be seen.

#### Benign neoplastic lesions

##### Giant cell tumor

These are large, red brown tumors that frequently undergo cystic degeneration. They are mostly composed of uniform oval mononuclear cells that constitute the proliferating component of tumor. Scattered within this background are numerous osteoclast type giant cells having 100 or more nuclei. (**Photo – 1**)

**Photo – 1:** Abundance of multinucleated giant cells with background of mononuclear stromal cells.

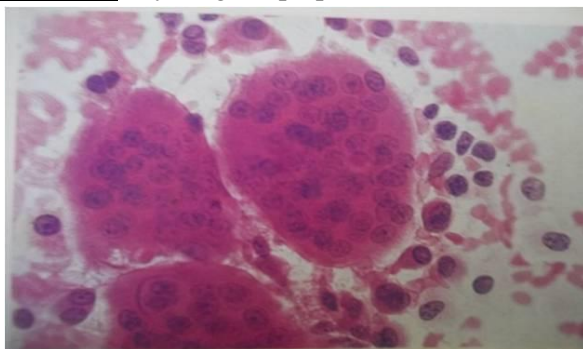

Necrosis, hemorrhage, hemosiderin deposition and reactive bone formation are common secondary features. Grade-I (conventional giant cell tumour), these tumours shows many giant cells with plenty of nuclei located in central with abundant cytoplasm, Grade-II, Grade-III



(aggressive morphology) in which number of giant cells were too less, number of nuclei in giant cells were less with atypical nuclear morphology and nuclei were arranged at the periphery of cell. Stromal cells were having aggressive nuclear morphology (**Photo – 2**).

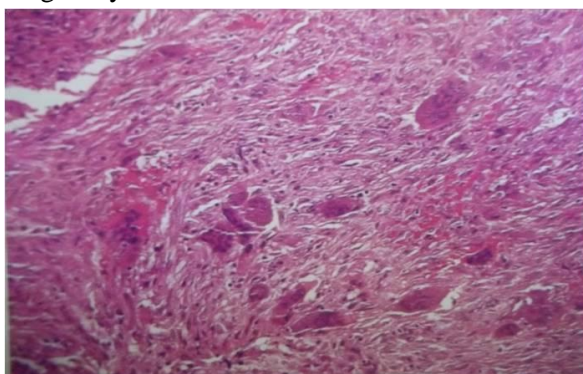
**Photo – 2:** Cytological preparation.



### **Fibrous dysplasia**

Irregular, curvilinear bony trabeculae (Chinese letter pattern) lined by very few osteoblast in the background of bland fibrous stroma. Nodules of hyaline cartilage with the appearance of disorganized growth plate in approximately 20% of cases. Cystic degeneration, hemorrhage and foamy macrophages are other common findings (**Photo – 3**).

**Photo – 3:** The predominant element is a spindle cell of fibroblastic appearance. There are also irregularly scattered osteoclasts.

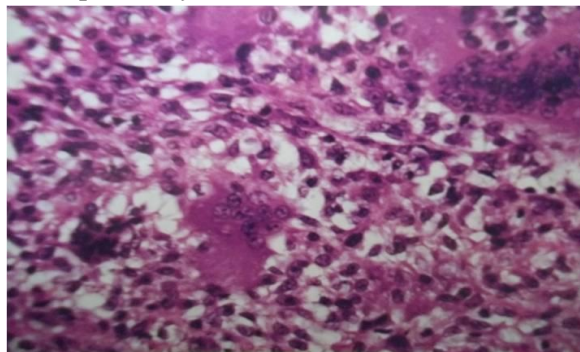


### **Chondroblastoma**

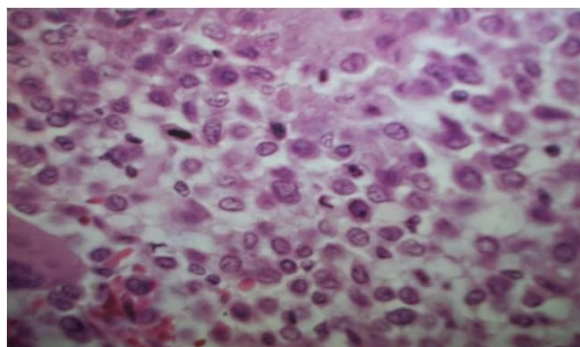
Sheets of compact polyhedral chondroblast having well defined cytoplasmic borders, moderate amounts of pink cytoplasm and coffee-bean shaped nuclei along with hyaline matrix and giant cells. Mitotic activity and necrosis are

frequently present. When the matrix calcifies it produces a characteristic chicken wire pattern of mineralization (**Photo – 4, 5**).

**Photo – 4:** Small round tumor cells are accompanied by scattered osteoclasts.



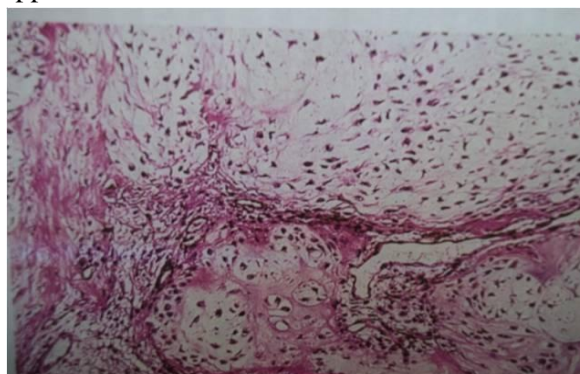
**Photo – 5:** Histiocyte like appearance of the nuclei of chondroblastoma cells.



### **Enchondroma**

It is composed of well circumscribed nodules of cytologically benign hyaline cartilage containing bland appearing chondrocytes. The peripheral portion of nodules may undergo enchondral ossification and the center can calcify and die (**Photo – 6**).

**Photo – 6:** The tumor has typical lobulated appearance.



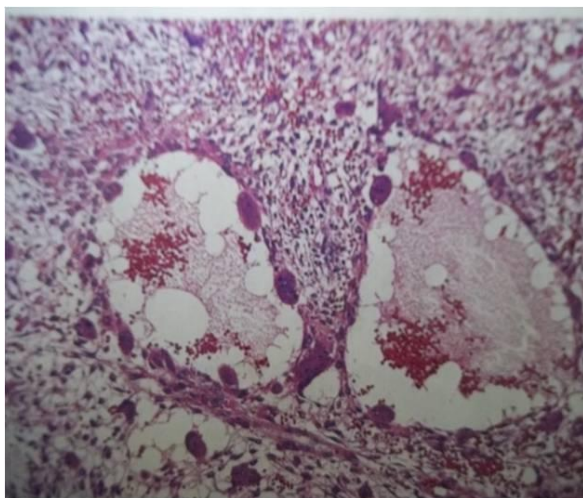
### **Simple bone cysts**

Cystic cavity lined by bland cell.

### **Aneurysmal bone cysts**

Multiple hemorrhagic cystic spaces separated by thin tan white septa and surrounded by bland fibrous stroma containing multi-nucleated osteoclast like giant cell and reactive woven bone (**Photo – 7**).

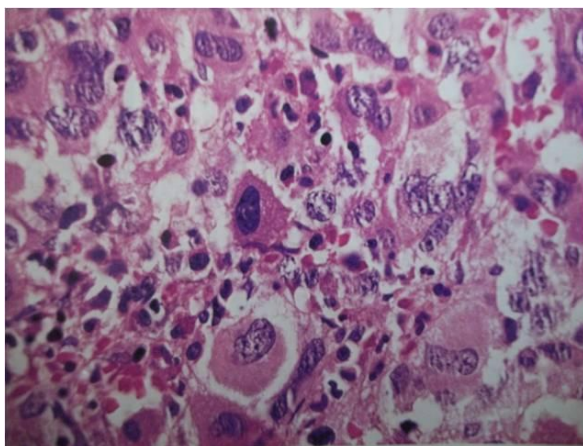
**Photo – 7:** Two cyst cavities lined by osteoclast like multinucleated giant cells. The intervening stroma is cellular but contains no neoplastic oteoid.



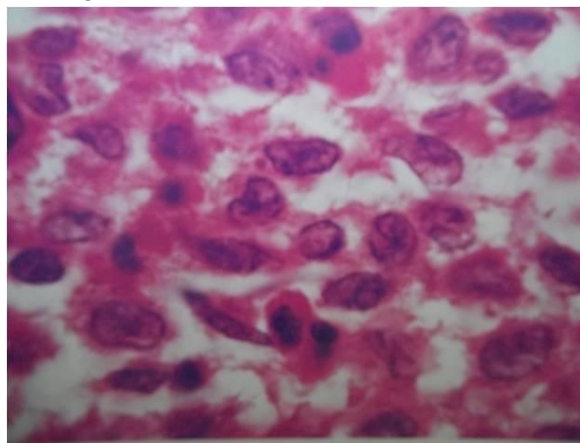
### **Langerhans cell histiocytosis**

Plenty of eosinophils in the background of coffee bean shaped multi-lobated histiocyte (**Photo – 8, 9**).

**Photo – 8:** Polymorphic appearance resulting from mixture of langerhan cells, neoplastic histiocytes, lymphocytes and eosinophils.



**Photo – 9:** High power view showing elongated nuclei with occasional longitudinal grooves in the langerhans cells.

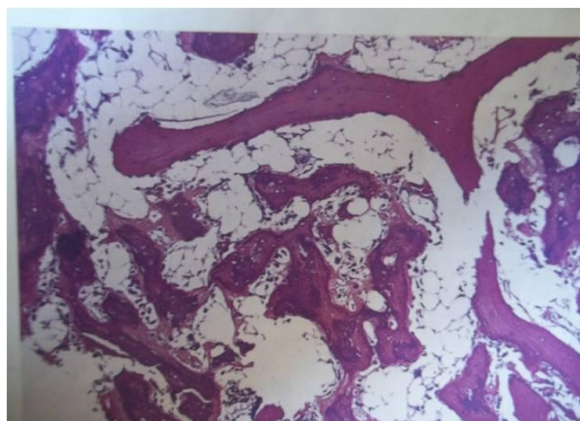


### **Malignant lesion**

#### **Osteosarcoma**

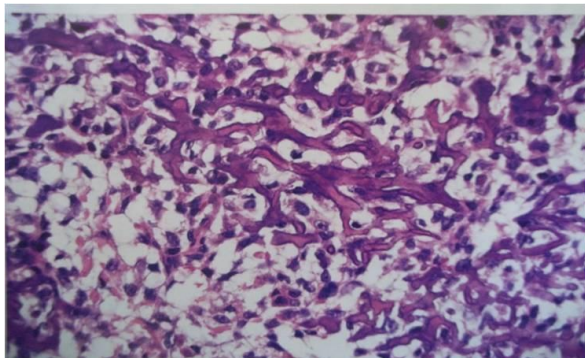
The tumor cells vary in size and shape and frequently have large hyper chromatic nuclei. Bizzare tumor giant cells are common as mitoses. The formation of bone by the tumor cells is characteristic. The neoplastic bone usually has coarse, lace like architecture but also may be deposited in broad sheets or primitive trabeculae. Other matrices, including cartilage or fibrous tissue, may be present in varying amounts. When the malignant cartilage is abundant, the tumor is called chondroblastic osteosarcoma. Vascular invasion is usually conspicuous, and up to 50 to 60% of an individual tumor may be necrotic (**Photo – 10, 11**).

**Photo – 10:** The malignant bone is more basophilic and has more irregular borders.





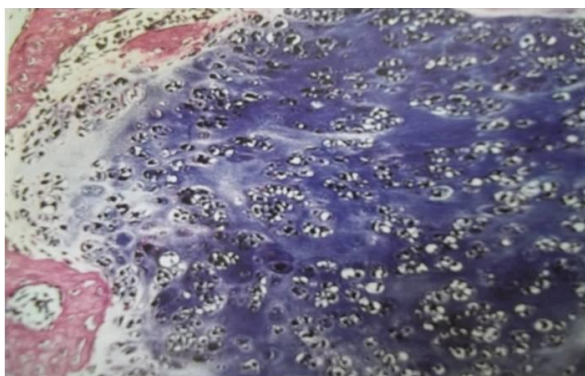
**Photo – 11:** Characteristic basophilic thin bony trabeculae of neoplastic bone.



### Chondrosarcoma

Conventional chondrosarcoma is composed of malignant hyaline and myxoid cartilage. Low grade or grade 1 lesions demonstrate mild hypercellularity and the chondrocytes have plump vesicular nuclei with small nucleoli. Binucleate cells are sparse and mitotic figures are difficult to find. Portions of the matrix frequently mineralize and the cartilage may undergo enchondral ossification. By contrast grade 3 are characterized by marked hypercellularity, extreme pleomorphism with bizarre tumor giant cells and mitoses (**Photo – 12, 13, 14**).

**Photo – 12:** Well differentiated chondrosarcoma. The tumor has a distinctly lobulated quality.

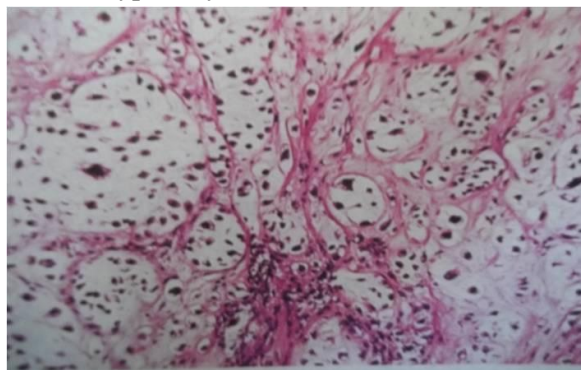


### Ewing's sarcoma

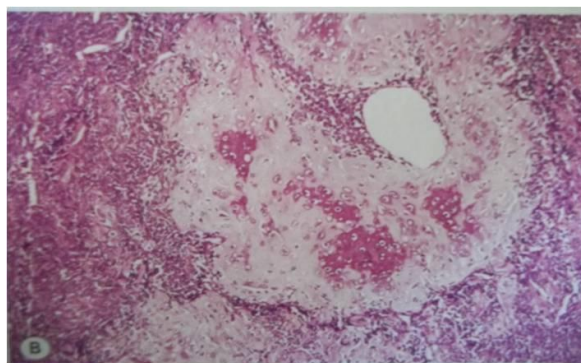
Uniform small blue round cells having very scanty cytoplasm which may appear clear because it is rich in glycogen, arranged in a sheets separated by fibrovascular stroma. The presence of Homer Wright rosettes (tumor cells arranged in a circle about a central fibrillary space) is indicative of neural differentiation.

Necrosis may be prominent, and there are relatively few mitotic figures in relation to the dense cellularity of the tumor (**Photo – 15**).

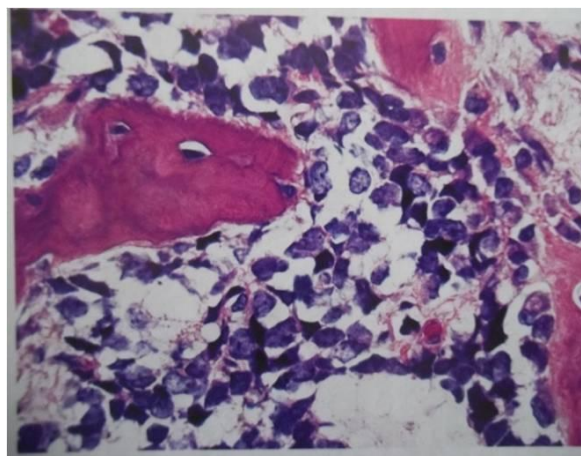
**Photo – 13:** Well differentiated chondrosarcoma. The tumor retains a lobulated appearance, but nuclear atypicity is obvious.



**Photo – 14:** Mesenchymal chondrosarcoma: an island of well differentiated cartilage in the center.



**Photo – 15:** Uniform cells with darkly staining nuclei and very scanty cytoplasm infiltrate marrow spaces around the bony trabeculae.



### **Synovial sarcoma**

Morphologically, it is monophasic or biphasic. The histological hallmark of biphasic is dual lines of differentiation (epithelial like and mesenchymal like). Monophasic being composed of only spindle cells or very rarely epithelial cells

### **Metastasis**

Lung carcinoma metastasized to bone consisting of squamous cell carcinoma shows pleomorphic squamous epithelial cells in the back ground of bony trabeculae. Adenocarcinoma of lung were showing malignant columnar cell arranged in adenoid pattern, which were confirmed at higher centre by IHC, tumors were positive for CEA and TTF-1.

### **Discussion**

This study was carried out precisely to diagnose different lesions of bone. One of the important points to be considered is the age of the patient. Some of the bone lesions are most probably confined to certain age groups such as: metastatic neuroblastoma in the infant and young child, metastasis and multiple myeloma in the middle-aged and elderly, lymphomas affecting only bone usually occur during adult life; most cases after 25 years of age.

Ewing's sarcoma and simple bone cyst in the long bones of children and young teenagers, and giant cell tumor in the young to middle-aged adult (20 to 50 years of age). Even the most common age group of all bone lesions was 25-50 years, in which total 45 cases of bone lesions were found composed of 31 cases of non neoplastic lesions, 10 cases of benign neoplastic lesions and 4 cases of malignant neoplastic lesions.

In our study, out of 102 cases of bone lesions, most common were non neoplastic lesions making 76 cases. Osteomyelitis implies inflammation of bone and marrow; it may be complication of any systemic infection but frequently manifest as a primary solitary focus of disease. All types of organisms including viruses,

parasites, fungi and bacteria can produce osteomyelitis.

### **Pyogenic osteomyelitis**

Organisms reach the bone by hematogenous spread, direct implantation and Extension from a contiguous site. Culprit organisms are Staphylococcus aureus responsible for 80% to 90% of cases, Escherichia coli, Pseudomonas and Klebsiella are most frequently isolated from individuals with genitourinary tract infection or who are intravenous drug abusers and Mixed bacterial infection in case of direct spread or inoculation of organisms during surgery or open fractures, Hemophilus influenza and group B streptococci in neonatal period. In almost 50% of cases, no organism can be isolated. Osteomyelitis was found in all age groups above ten years. The diagnosis of chronic recurrent multifocal osteomyelitis is essentially one of exclusion. Infective osteomyelitis and malignancy are the main differential diagnoses [7, 8].

### **Tuberculous osteomyelitis**

The affected individuals are usually adolescents or young adults. The organisms are usually blood borne and originate from focus of active visceral disease during the initial stages of primary infection. Direct extension may also occur. The bony infection is usually solitary. The spine (40 % of cases, especially the thoracic and lumbar vertebrae) followed by the knees and hips are the most common sites. Typically affected individuals present with pain on motion, localized tenderness, low grade fevers, chills and weight loss. The osteolytic lesions of tuberculosis at multiple sites need to be differentiated from multiple myeloma, secondary metastasis, Ewing sarcoma, Lymphoma and bacterial osteomyelitis. Delay in diagnosis is usually due to the patients presenting late or it may be due to lack of awareness and its insidious onset. Histopathological examination yields a high percentage of positive results [9].

In our histopathological study, tuberculosis was more common than bacterial osteomyelitis in inflammatory bone lesions and mostly found in elderly age groups. Neoplastic lesions were 26



cases, amongst neoplastic lesions, 18 cases of benign and 8 cases of malignant lesions were found. Out of 18 benign neoplastic bone lesions, 4 cases were of giant cell tumour and 4 cases were of osteochondroma (exostosis) bone.

### **Giant cell tumor**

It is the most common bone tumor, accounts for 5 to 9 percent of all primary bone tumors. In present study, the most common site of giant cell tumor was lower end of femur and upper end of tibia. It is usually seen in patients over 20 years of age. It is more common in women than in men. The classic location is the epiphysis of long bone, from which it may spread into the metaphyseal area, break through cortex, invade the inter muscular septa or even cross a joint space. The sites most commonly affected (in order of frequency) are the lower end of femur, the upper end of the tibia, the lower end of radius and also occurs in humerus, fibula and skull bone, particularly the sphenoid bone. Most patients present with slowly progressive pain, with or without a mass. Symptoms arise when the lesion begins to destroy the cortex and irritate the periosteum or when the weakening of the bone caused by the tumor causes pain due to imminent pathologic fracture. Some giant cell tumors present with a pathologic fracture. Radiological findings demonstrate the typical appearance of a giant cell tumor is that of an entirely lytic, expansile lesion in the epiphysis usually without peripheral bone sclerosis or periosteal reaction, lesion is most often eccentrically placed to the long axis of the bone [10, 11].

### **Osteochondroma**

The most common location of osteochondroma are the metaphyses of the lower femur, upper tibia, upper humerus and the pelvis. The average of the patient at onset is approximately 10 years, in the large majority of the cases, the tumor appear before the patient is 20 years old. It is usually asymptomatic, but it may lead to deformity or interfere with the function of adjacent structure such as tendons and blood vessels. It may also undergo spontaneous

regression. The radiographic appearance is very characteristic, one of the most typical features is the fact that lesions when located in metaphyses of long bones, grow out in direction opposite to the adjacent joint [12]. In our study, out of 102 cases of bone lesions, most common primary malignant lesion were osteosarcoma and metastasis.

### **Osteosarcoma**

It usually occurs in patient between 10 and 25 years of age, another peak age incidence occurs after 40. Most rise *denovo*, but others arise within context of pre-existing conditions like paget disease, radiation exposure, chemotherapy, pre-existing benign bone lesions, foreign bodies, trauma and genetic predisposition [13]. Osteosarcoma can arise in any bone of the body but majority originate in long bones of appendicular skeleton, especially the distal femur, followed by the proximal tibia and proximal humerus- sites containing the most proliferative growth plates. In the long bones the tumour is most frequently centered in the metaphysis (90%), infrequently in the diaphysis (9%), and rarely in epiphysis.

### **Chondrosarcoma**

It is the malignant tumor of cartilage forming tissues. Two major categories on the basis of microscopic criteria are identified. Conventional chondrosarcoma and Chondrosarcoma variants such as clear cell, myxoid (chondroid), dedifferentiated, mesenchymal and granular cell chondrosarcoma are present. Three categories according to location Central, Peripheral and Juxtacortical (Periosteal) are identified [14].

### **Metastasis**

Pain, pathological fractures and hypercalcemia are the major sources of morbidity with bone metastasis. Pain is the most common symptom found in 70% patients with bone metastases caused by stretching of the periosteum by the tumor as well as nerve stimulation in the endosteum. Pathological fractures are most common in breast cancer due to the lytic nature of the lesions. Hypercalcemia only occurs in

10% of patients [15]. In our study three cases of metastatic lytic lesion were found, which included Squamous Cell Carcinoma of lung and adenocarcinoma of Lung metastasize to upper end of humerus presented with pain, weight loss and non healing pathological fracture. All the three cases had shown increase level of alkaline phosphatase while adenocarcinoma of lung with metastasis to bone found to have hypercalcemia.

## Conclusion

Finally we concluded that bone lesions are very common radiological finding for Orthopedic surgeon in many patients. Even an Orthopedic surgeon and radiologist together will not be able to reach to the precise conclusion and further treatment. Histopathology is the gold standard for the precise diagnosis from a very large number of conditions leading to bone lesions.

## References

1. Bonetumor.org, (internet), Massachusetts, Henry Degroot, Bone metastasis, Available from, <http://www.bonetumor.org/tumors/pages/page67.htm>. Accessed on 20-11-2015.
2. Dirschl DR. Acute pyogenic osteomyelitis in children. *Orthop Rev.*, 1994; 23(4): 305-12.
3. Chawla KP, Pandit AA, Jaiswal PK, Ahuja A. Osteoarticular tuberculosis with involvement of multiple sites (a case report). *J Postgrad Med.*, 1990; 36: 171.
4. Cancer.org (internet), Atlanta, American cancer society, Detailed guide, bone metastasis. Available from [http://www.cancer.org/docroot/CRI/content/CRI\\_2\\_4\\_1X\\_What\\_Is\\_bone\\_metastasis\\_66.asp?sitearea=](http://www.cancer.org/docroot/CRI/content/CRI_2_4_1X_What_Is_bone_metastasis_66.asp?sitearea=). Accessed on 24-11-2015.
5. Manaster BJ. Tumors. In: Manaster BJ, Disler DG, May DA, eds. *Musculoskeletal Imaging: The Requisites*, 2<sup>nd</sup> edition, St. Louis, MO: Mosby; 2002, p. 1-104.
6. Resnick D. Tumors and tumor-like lesions of bone: Imaging and pathology of specific lesions. In: Resnick D, ed. *Bone and Joint Imaging*, 2<sup>nd</sup> edition, Philadelphia, PA: W.B. Saunders; 1996, p. 991-1063.
7. L P Robertson, P Hickling. Chronic recurrent multifocal osteomyelitis is a differential diagnosis of juvenile idiopathic arthritis. *Ann Rheum Dis.*, 2001; 60: 828-831.
8. Walker GF. Failure of early recognition of skeletal tuberculosis. *Brit Med J.*, 1968; 1: 682-683.
9. Lakhanpal VP, Tuli SM, Singh H, Sen PC. The value of histology, culture and guinea pig inoculation examination in osteo-articular tuberculosis. *Acta Orthop Scand.*, 1974; 45: 36-42.
10. Saigal MD, Wahi PN, Singh CB. Lymph node and synovial membrane biopsies in diagnosis of joint tuberculosis. *Ind J Med Sci.*, 1954; 8: 536-540.
11. Gielis: GCT Huvos Orthopedic Pathology Bullough Orthopedic Pathology HD4/6/2003.
12. Dorfman H, Czerniak B, et al. WHO classification of tumours of bone: introduction. In: Fletcher CDM, Unni KK, Mertens F, eds. *World health organization classification of tumours. Pathology and genetics of tumour of soft tissue and bone*. Lyon: IARC Press; 2002.
13. Vinholes J., et al. Effects of Bone Metastases on Bone Metabolism: Implications for Diagnosis, Imaging and Assessment of Response to Cancer Treatment. *Cancer Treatment Reviews*, 1996; 22: 289-331.
14. Stoll B., Parbhoo S. *Bone Metastasis*, Raven Press Books, Ltd., New York, NY, 1983, p. 14.
15. Rosai and Ackerman's *Surgical pathology*, 10<sup>th</sup> edition, Mosby, 2011.