

Original Research Article

# A descriptive study on formation and branching of brachial plexus in adult human cadavers of West Bengal


Sujata Manna<sup>1</sup>, Mousum Mahanti<sup>1\*</sup>, Ramanuj Singh<sup>2</sup>, Alpana De Bose<sup>3</sup>

<sup>1</sup>Assistant Professor, <sup>2</sup>Associate Professor

Department of Anatomy, Gouri Devi Institute of Medical Sciences and Hospital, Rajbandh, Durgapur, West Bengal, India

<sup>3</sup>HOD, Department of Anatomy, R. G. Kar Medical College and Hospital, Kolkata, West Bengal, India

\*Corresponding author email: [mousummahanti@gmail.com](mailto:mousummahanti@gmail.com)

	International Archives of Integrated Medicine, Vol. 4, Issue 12, December, 2017. Copy right © 2017, IAIM, All Rights Reserved. Available online at <a href="http://iaimjournal.com/">http://iaimjournal.com/</a> ISSN: 2394-0026 (P)ISSN: 2394-0034 (O)
	Received on: 19-11-2017 Accepted on: 30-11-2017 Source of support: Nil Conflict of interest: None declared.
<b>How to cite this article:</b> Sujata Manna, Mousum Mahanti, Ramanuj Singh, Alpana De Bose. A descriptive study on formation and branching of brachial plexus in adult human cadavers of West Bengal. IAIM, 2017; 4(12): 1-4.	

## Abstract

Variation in anatomy of brachial plexus is important for surgeons working in the upper limb area. It is equally important for anaesthetists performing brachial plexus block as well as neurologists assessing neuronal pathology. The present study was conducted to find the anatomical variations in formation and branching of brachial plexus in adult human cadavers of West Bengal. A total of 54 upper limbs in 27 cadavers were included in this study and were assessed for its course from its formation in cervical region to its termination into branches in the upper extremity. Four plexus were prefixed in origin. Middle and lower trunk were fused in one limb. Lateral cord variations included absence of musculocutaneous nerve in three limbs and extra lateral root of median nerve in one case. Posterior cord variation included two thoracodorsal nerves in two cases. Communicating branch between musculocutaneous nerve was found in three limbs and between radial and ulnar nerve in one limb. In one case, high division of radial nerve was seen. The present study indicated that there are variations in anatomy of brachial plexus and awareness of its pattern is important for those dealing with procedures involving brachial plexus.

## Key words

Brachial Plexus, Formation, Branching, Anatomy, Variations, Cadaveric Study.

## Introduction

The brachial plexus is formed by ventral rami of spinal cervical nerves (C5-C8) and first thoracic spinal nerve. It consists of three cords forming behind the clavicle and entering upper part of axilla above the axillary artery, second part of which is encircled by the cords of brachial plexus. Upper two roots unite to form upper trunk, the middle one gives rise to central trunk and lower two roots form lower trunk [1]. Formation and branching of brachial plexus is complex and it is anatomically related to important structures [2]. Various workers have reported about variations in formation and branching of brachial plexus [3]. The present study tries to fill the gap in knowledge about these anatomical variations in West Bengal population.

## Aim and objectives

The present study was conducted to assess the neuroanatomical variations in formation and branching of brachial plexus in adult human cadavers of West Bengal.

## Materials and methods

The present study was descriptive in nature conducted upon 54 upper limbs in 27 cadavers in the anatomy department of a tertiary medical institution of West Bengal. Exclusion criteria were damage or surgical intervention of the brachial plexus.

Brachial plexus was studied in its entire course from the formation in cervical region, course through root of the neck, axilla and up to the terminal branches into the major nerves of the upper extremity. Careful dissection was done to find its formation, course and termination. As per Cunningham's manual of practical Anatomy, the upper arm, axilla and posterior triangle of the neck on same side were dissected successively by cutting skin, superficial fascia, deep fascia,

the pectoralis major and pectoralis minor muscles. To identify the three cords of brachial plexus (lateral, medial and posterior), the infraclavicular part was dissected. Relationship to the second part of the axillary artery posterior to the pectoralis minor muscle was seen to name the cords.

Scale and thread was used for measurements. Data was entered in Microsoft Excel 2007 and analysed using SPSS v 16.0. All the information was kept confidential and was used for research purposes only.

## Results and Discussion

Formation of brachial plexus (**Chart – 1**) - Usual origin (C<sub>5</sub>-T<sub>1</sub>) was seen in 49 plexus (90.7%, 95% CI- 79.7-96.9%), prefixed (C<sub>4</sub>-T<sub>1</sub>) was seen in four (7.4%, 95% CI- 2.1-17.9%) and post-fixed (C<sub>5</sub>-T<sub>2</sub>) in one (1.9%, 95% CI- 0.0-9.9%). Middle and lower trunk were fused in one limb (1.9%, 95% CI- 0.0-9.9%). Upper and middle trunk fusion was not seen. Gopal, et al. did not find any variation in formation of trunks. However they observed that the lateral cord communicated with the medial root of median nerve and ulnar nerve both in one specimen (2.5%) on right side [3]. Uysal, et al. have reported that the superior and inferior trunk formation was absent in 1% and 9% cases respectively. They also found prefixed plexus in 25.5% of cases and postfixed plexus in 2.5% of cases [4]. Malukar and Rathva found fusion of lateral and medial cord in one case only [5]. Das, et al. reported that there is an additional root in the formation of median nerve in one case [6].

Branching pattern of brachial plexus was as per **Table – 1**. Singhal, et al. reported that the lower trunk divided into one anterior and two posterior divisions. The anterior division fused with the posterior divisions of middle trunk and the upper trunk to give rise to the medial root of the median nerve, medial cutaneous nerve of the

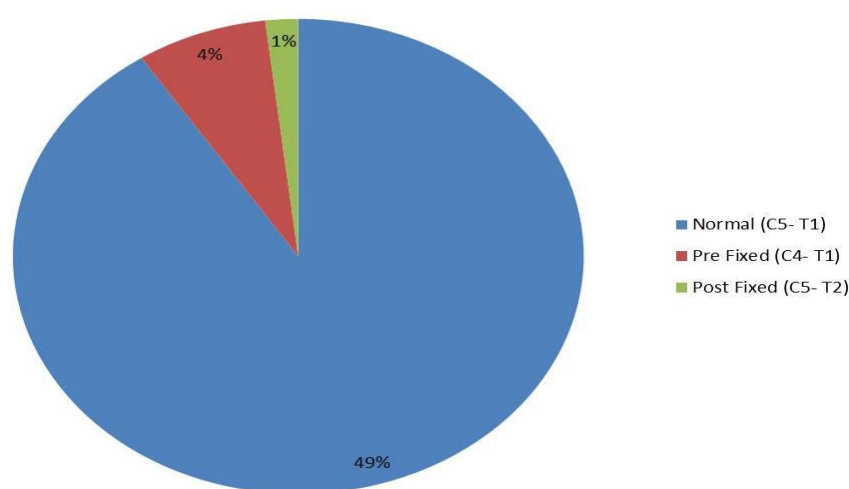
arm, the medial cutaneous nerve of forearm and continued as the ulnar nerve. The posterior divisions joined the radial nerve [7].

Gopal, et al. found that the musculocutaneous nerve communicates with the medial root of median nerve on the left side before piercing the coracobrachialis muscle (2.25%) and in other two (5.0%), it joined after piercing the coracobrachialis muscle on the same side in one

specimen [3]. Bergman, et al. found that musculocutaneous nerve arose from the lateral cord in 90% cases and is arising from the median nerve or is absent in 2% cases [8]. Malukar and Rathva observed absence of musculocutaneous nerve in 10% cases where median nerve supplied coracobrachialis, biceps brachii and brachialis and turned into lateral cutaneous nerve of forearm [5].

**Chart – 1:** Formation of brachial plexus.

**Chart showing formation of brachial plexus**



**Table – 1:** showing branching pattern of brachial plexus.

Cords	Variation	Frequency
Lateral	Absence of musculocutaneous nerve	3 (5.6%, 95% CI- 1.2-15.4%)
	Extra lateral root of median nerve	1 (1.9%, 95% CI- 0.0-9.9%)
Medial	Medial root of median nerve not originating from medial cord	2 (3.7%, 95% CI- 0.5-12.7%)
Posterior	Two thoracodorsal nerves	2 (3.7%, 95% CI- 0.5-12.7%)
	Division in two roots and union into radial nerve	1 (1.9%, 95% CI- 0.0-9.9%)

Median nerve formed at the level of axilla in 74.1% (95% CI- 60.3-85.0%), upper 1/3<sup>rd</sup> of arm in 16.7% (95% CI- 7.9-29.3%) and lower 1/3<sup>rd</sup> of arm in 9.2% (95% CI- 3.1-20.3%) cases. Point of origin of median nerve lied lateral to axillary artery in 72.2% (95% CI- 58.4-83.5%) cases. Median nerve was lateral to brachial artery in all cases except one where it was medial. Gopal, et al. have reported that the medial root of median nerve joined the ulnar nerve on the left limbs in two cases (5%) [3]. Chauhan, et al. found that the

median nerve formed by two lateral and one medial roots [9]. Malukar and Rathva observed eight cases of communication between musculocutaneous and median nerve [5].

Axillary nerve originated from posterior cord and lied posterior to 3<sup>rd</sup> part of axillary artery in all cases. It did not communicate with any other nerve. Darji, et al. found communication between radial and axillary nerve in only one case [10].

Ulnar nerve originated from medial cord in 98.1% (95% CI- 90.1-100%) cases. It lied medial to 3<sup>rd</sup> part of axillary artery in all cases. Gopal, et al. found that one case of left limb the ulnar nerve received a communicating branch from medial root of median [3]. Gupta, et al. found a communicating branch between ulnar and radial nerve which originated 0.9 cm distal to origin of ulnar nerve [11].

Radial nerve originated from posterior cord and lied posterior to 3<sup>rd</sup> part of axillary artery in all cases. In one case, high division of radial nerve was seen. Communicating branch between musculocutaneous nerve was found in three limbs and between radial and ulnar nerve in one limb. Bhat KMR, et al. found that after formation of posterior cord, the cord had divided again into two roots and enclosed the subscapular artery. Then, these two roots fused to continue as radial nerve [12].

As it is evident from the above discussion, many variations were seen in formation and branching of brachial plexus. It was more common in musculocutaneous and median nerves. This knowledge is essential for clinicians dealing with unusual symptoms and surgeons operating on axillary area and upper arm to avoid damage to the important nerves.

## Conclusion

The present study indicated that there are variations in anatomy of brachial plexus and awareness of its pattern is important for those dealing with procedures involving brachial plexus.

## References

1. Gray H. Gray's Anatomy: The Anatomical Basis of Clinical Practice. 39<sup>th</sup> edition. Edinburg: Elsevier Churchill Livingstone, 2005, p. 803-804, 846-847.
2. Williams P, Bannister L, Berry M. Nervous system. In Gray's Anatomy,

- 38<sup>th</sup> edition. Edinburgh: Churchill Livingstone, 1995, p. 1266-1272.
3. Gopal K, Anurag, Singh O. Anatomical variations of brachial plexus: anomalous branching pattern. Int J Res Med Sci., 2016; 4: 3376-80.
4. Uysal II, Seker M, Karabulut AK, et al. Brachial plexus variations in human fetuses. Neurosurgery, 2003; 53(3): 676-84.
5. Malukar O, Rathva A. A study of 100 cases of Brachial plexus. Nat J Comm Med., 2011; 166-70.
6. Das S, Paul S. Anomalous branching pattern of lateral cord of brachial plexus. Int J Morphol., 2005; 23: 289-92.
7. Singhal S, Rao VV, Ravindranath R. Variations in brachial plexus and the relationship of median nerve with the axillary artery: a case report. Journal of Brachial Plexus and Peripheral Nerve Injury, 2007; 2: 21.
8. Bergman RA, Thompson SA, Afifi AK, Saadeh FA. Compendium of human anatomic variation: catalogue, atlas, and world literature. Baltimore, Munich: Urban and Schwarzenberg., 1988, 139-43.
9. Chauhan R, Roy TS. Communication between the median and musculocutaneous nerve: a case report. J AnatSoc India, 2002; 51(1): 72-5.
10. Darji A, Chauhan H, Khatri H, Aterkar S, Pensi C.A. Variations in branching pattern of brachial plexus : A cadaveric study. Int J Biomed Adv Res., 2013; 4(3): 174-178.
11. Gupta M, Goyal N, Harjeet. Anomalous communications in the branches of brachial plexus. J. Anat. Soc. India, 2005; 54(1): 22-25.
12. Bhat KMR, Grijavallabhan V. Variation in the branching pattern of posterior cord of brachial plexus. Neuroanatomy, 2008; 7: 10-11.