


Original Research Article

Evaluation of maxillofacial injuries using multi slice computed tomography in a tertiary care hospital

V. Aswin*

Assistant Professor, Department of Interventional Radiology and Imaging Sciences, Tamil Nadu Government Multi-Specialty Hospital, Omandurar Estate, Chennai, India

*Corresponding author email: drvaswinkumar@gmail.com

	International Archives of Integrated Medicine, Vol. 8, Issue 11, November, 2021. Available online at http://iaimjournal.com/ ISSN: 2394-0026 (P) ISSN: 2394-0034 (O)
	Received on: 25-10-2021 Accepted on: 03-11-2021 Source of support: Nil Conflict of interest: None declared. Article is under creative common license CC-BY
How to cite this article: V. Aswin. Evaluation of maxillofacial injuries using multi slice computed tomography in a tertiary care hospital. IAIM, 2021; 8(11): 15-30.	

Abstract

Background: CT has revolutionized imaging especially in parts of the human body with complex and intricate anatomy such as the maxillofacial region. It is therefore the examination of choice for evaluating fractures of the facial bones produced as a result of trauma.

Aim of the study: The purpose of this study was to describe the advantages of 3 –Dimensional and coronal reformatted images over axial images in the evaluation of various facial fractures and also to describe and classify the fractures according to the bones involved in the patients evaluated.

Materials and methods: This study was conducted in the year 2017-2018 at 12 months at the Department of Interventional Radiology and Imaging Sciences, Tamil Nadu government multi-specialty hospital, Omandurar estate, Chennai. Multi slice CT evaluation was done on 100 patients having fractures of the maxillofacial bones, using a 6 –Slice CT scanner; Siemens Somatom Emot-6.3D volume-rendered images as well as coronal multi planar reformatted (MPR) images were also reconstructed to assess and describe its advantages over routine axial images.

Results: The study showed a male preponderance and the age most commonly affected was 31 to 40 years. RTA was the most common mode of injury. Fractures in the maxillary and nasal- orbit-ethmoid region were the most common. 3D images were similar or superior to axial images (in all 3 aspects) in most patients except when the fractures involved thin bones of the naso-orbit-ethmoid and maxillary regions. Coronal images were found to be similar or superior in the detection of fractures in all 5 regions studied.

Conclusion: This study demonstrates the valuable role of Multi detector CT in the evaluation of maxillofacial fractures and in classifying them. The advantages of 3D images in the assessment of facial trauma could be described. 3D images were better in the identification of Le Fort fracture lines.

The coronal reconstructed images are superior in the detection of fractures in the orbit and maxilla. 3D images have a limited role in fractures involving the naso-orbit-ethmoid region and also when there is minimal fracture displacement.

Key words

Road traffic accident, Extra dural hemorrhage, Sub dural hemorrhage, Sub arachnoid hemorrhage, Temporomandibular joint.

Introduction

Maxillofacial trauma usually presents in the Emergency Department (Casualty) as either an isolated injury or as a part of poly trauma [1]. Due to the evolution of more effective emergency transportation facilities and advanced life support, even patients that are severely injured survive to reach specialized trauma centers which are increasingly successful in rescuing patients [2]. With such advances in trauma care, the severity of diagnosed facial injuries may thus increase. Such injuries are clinically important as the disruption of soft tissues and bones of the face causes facial disfigurement and asymmetry which may cause cosmetic as well as emotional concerns. This region is also associated with several important functions of daily living [3]. Plain radiographs have been the initial modality of imaging in these patients, but they can be inadequate due to the superimposition of bony structures. CT greatly simplifies interpretation MDCT, the cornerstone of modern emergency radiology, can easily detect and characterize injuries not only of the body and spine but also intracranial and maxillofacial injuries [4]. Despite a higher radiation dosage compared to conventional radiographs, CT is the imaging modality of choice to display the multiplicity of fragments, the degree of rotation and displacement, or if there is any skull base involvement. It is also used to assess which areas of facial injuries are stable or unstable for planning corrective or reconstructive surgery [5]. The advances in medical imaging techniques such as computer software algorithms in CT have made the generation of coronal and sagittal reconstructed images as well as 3-Dimensional images quick and economical [6]. There is no additional scanning or radiation dosage as the

images can be reconstructed from the same axial CT images. 3-Dimensional images may be superior in the localization of complex fractures involving multiple planes, in the perception of fracture displacement, and the assessment of facial symmetry [7]. However, their usefulness in minor trauma with little or no fracture displacement is much less [8]. As experienced radiologists use axial images in the interpretation of facial trauma, the utility of reconstructed images in cases of complex facial trauma may be assessed in detail.

Materials and methods

this study was conducted in the year 2017-2018 at 12 months at the department of Interventional Radiology and Imaging Sciences, Tamil Nadu government multi-specialty hospital, omandurar estate, Chennai.

Multi slice CT evaluation was done on 100 patients having fractures of the maxillofacial bones, using a 6 –Slice CT scanner; Siemens Somatom Emot- 6. 3D volume-rendered images as well as coronal multi planar reformatted (MPR) images were also reconstructed to assess and describe its advantages over routine axial images.

Inclusion Criteria: Patients with CT evidence of fracture of the maxillofacial bones.

Exclusion Criteria: Patients without any evidence of fracture of the maxillofacial bones, Patients with maxillofacial fractures in whom a CT examination is contraindicated e.g. Pregnancy (1st trimester), etc.

Data Acquisition: MDCT evaluation is done only on patients who satisfy the inclusion criteria

and only after getting their consent. All the CT scans in this study were performed using a 6-Slice CT scanner (Siemens Somatom Emot-6). Along with the axial images, Coronal-plane multi planar reformation (MPR) images were reconstructed with a 1.5 mm increment. Three-dimensional volume-rendering images were also obtained. The MDCT scans were reviewed using the clinical work station. The fractures detected on CT examination were classified according to the region involved. 3D images were compared with axial images and assessed under the headings – fracture detection, the extent of the

fracture, and displacement. Coronal images were compared with axial images for the detection of fractures.

Results

In this study group which comprised of a total number of 100 patients, the age at presentation ranged from 11 to 65 yrs. Most patients belonged to the 31- 40 and 21- 30 age groups with 27 and 26 patients respectively. There were 89 males (89%) and 11 females (11%) in the patients included in the study group (**Chart – 1**).

Chart - 1: Age distribution of patients presenting with facial fractures.

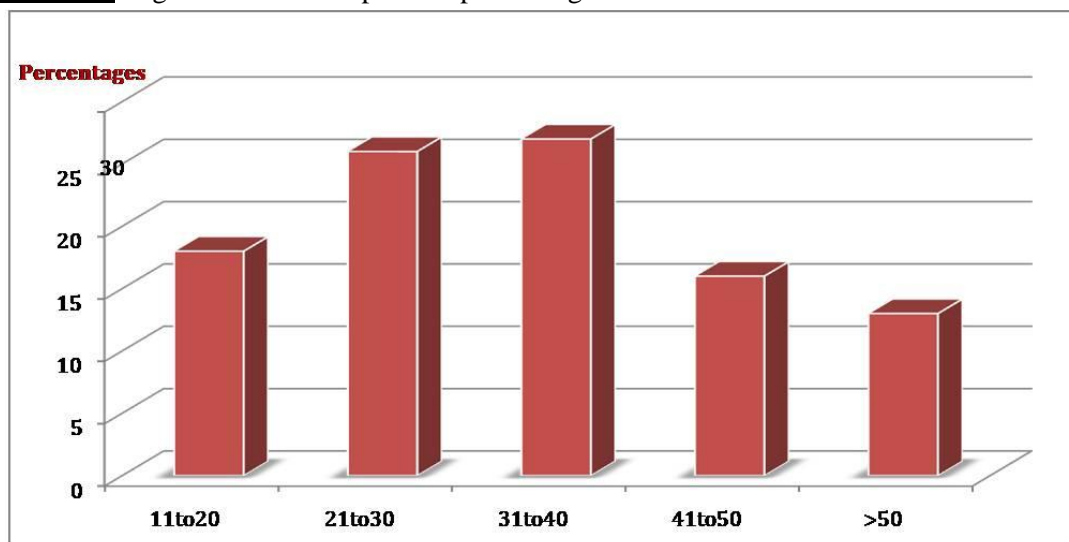


Chart - 2: Bar graph showing the different modes of injury.

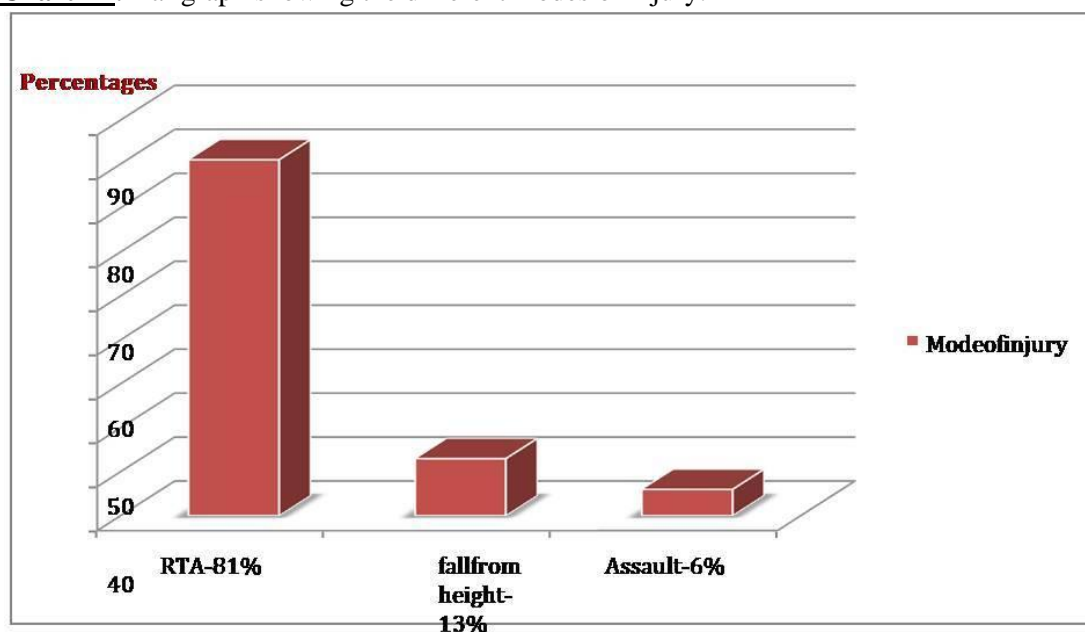
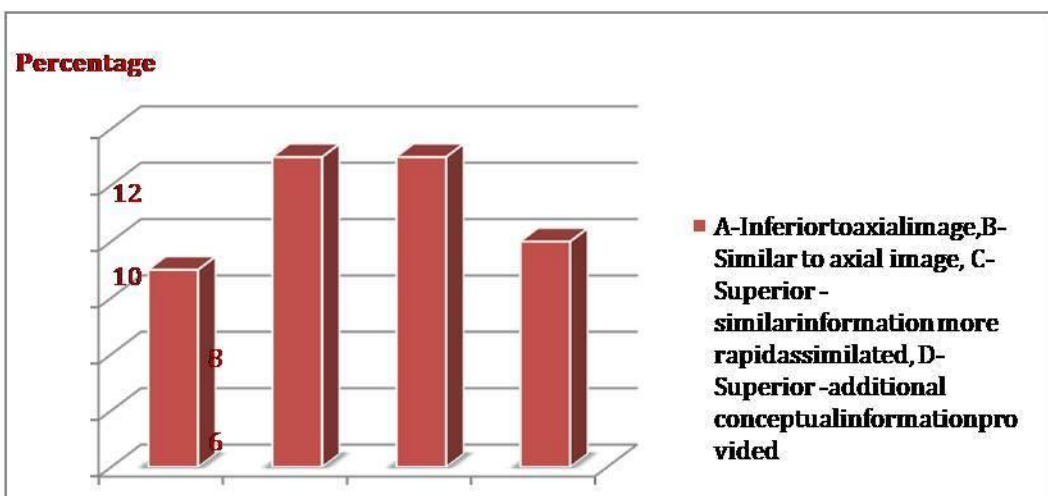
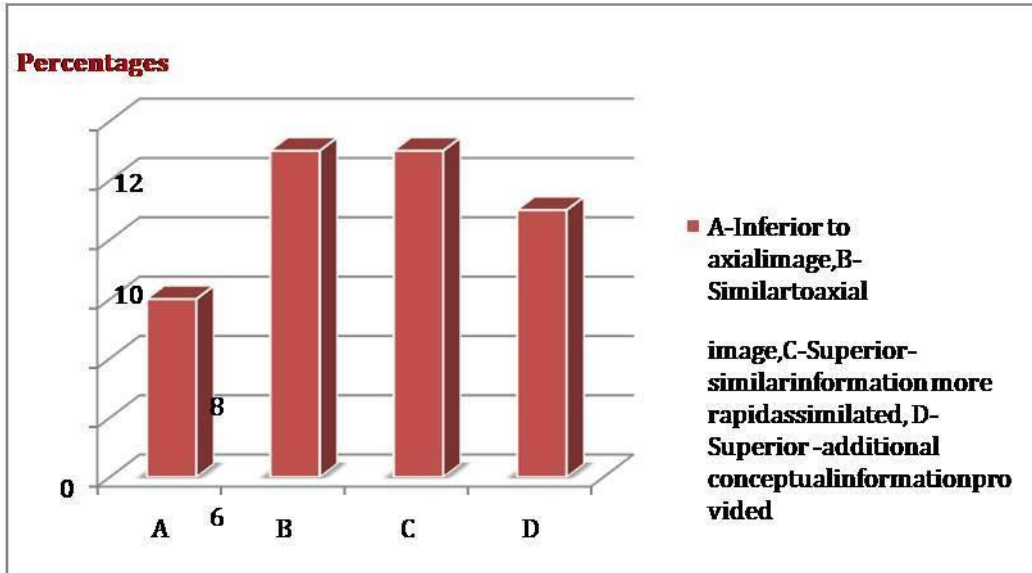
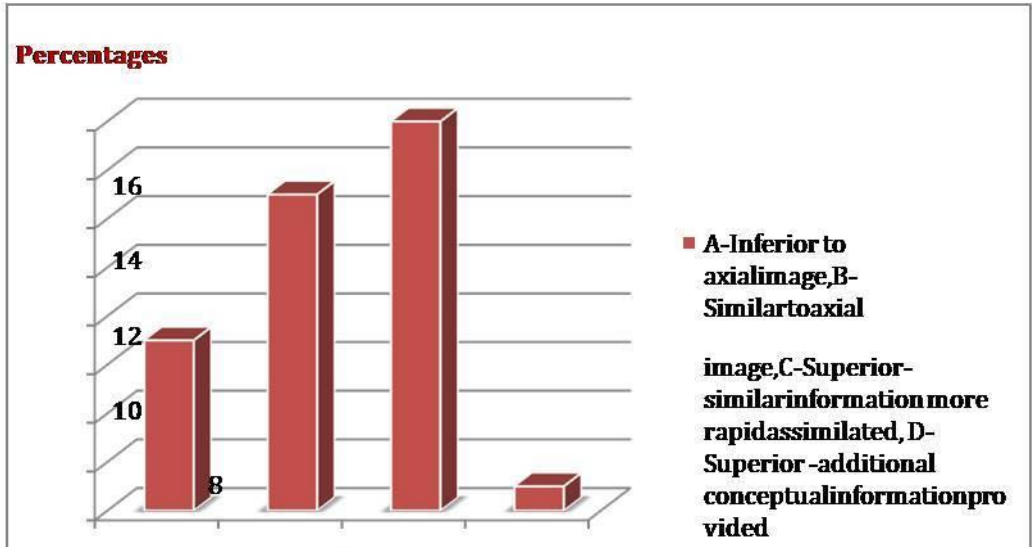


Chart – 3: Frontal bone fractures.



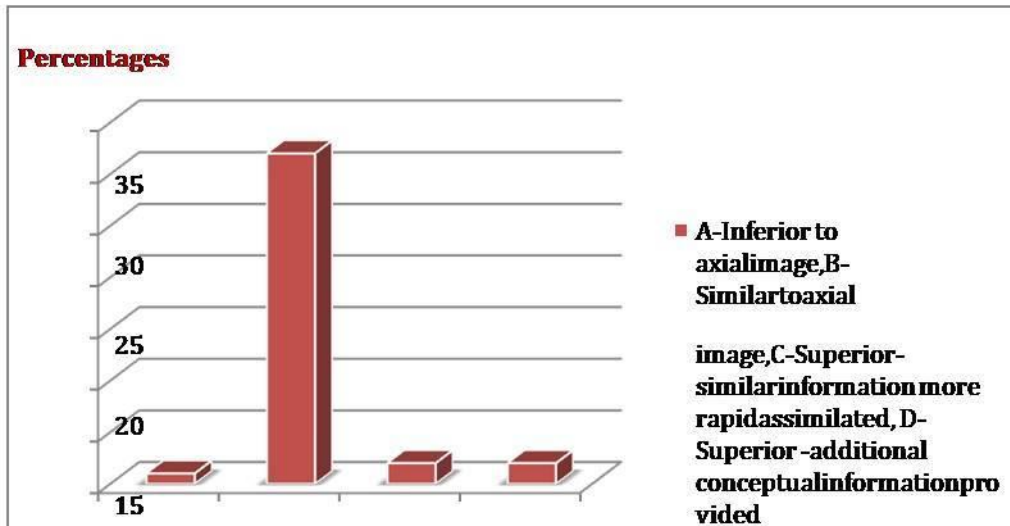
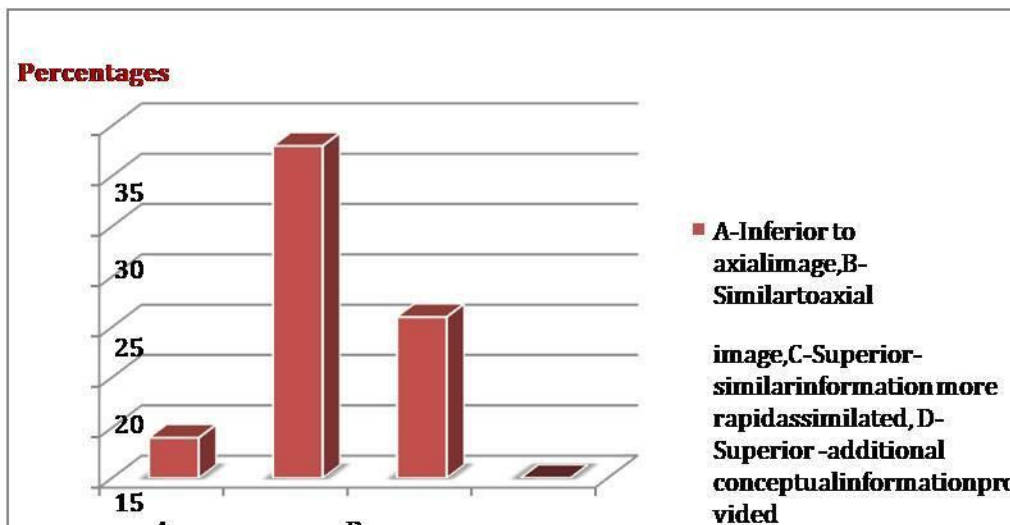
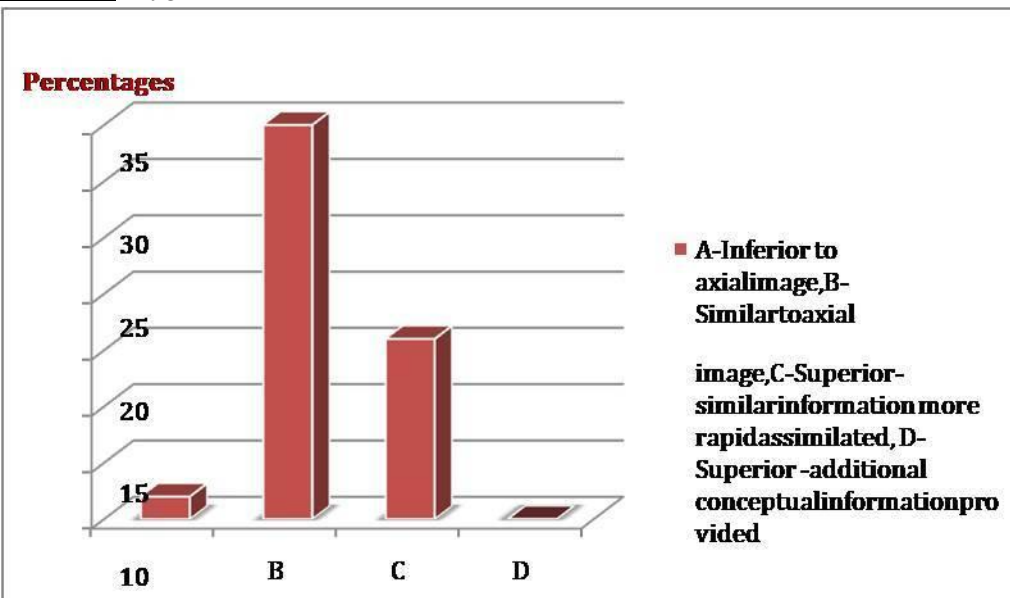


Chart – 4: Zygomatic Bone Fractures.



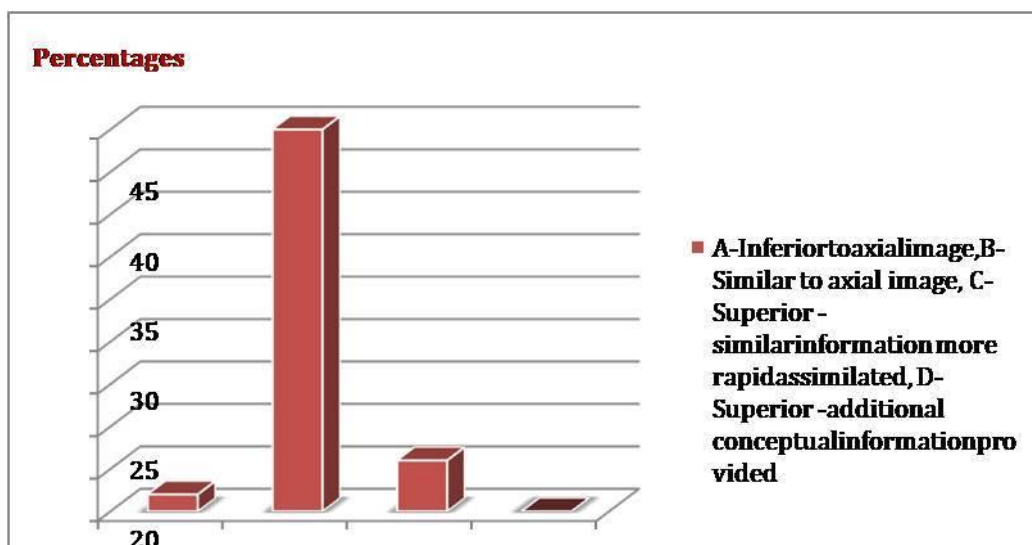
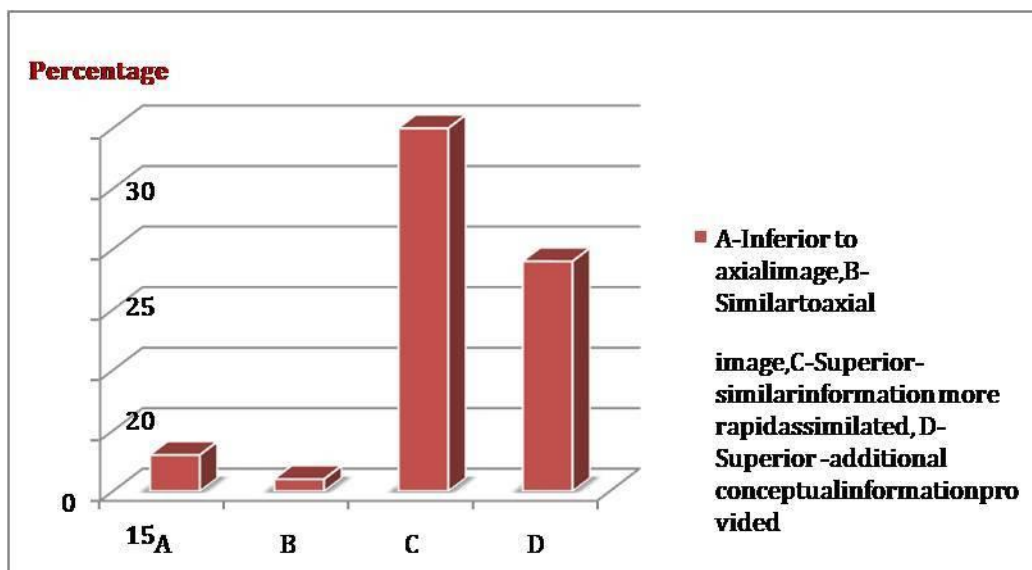
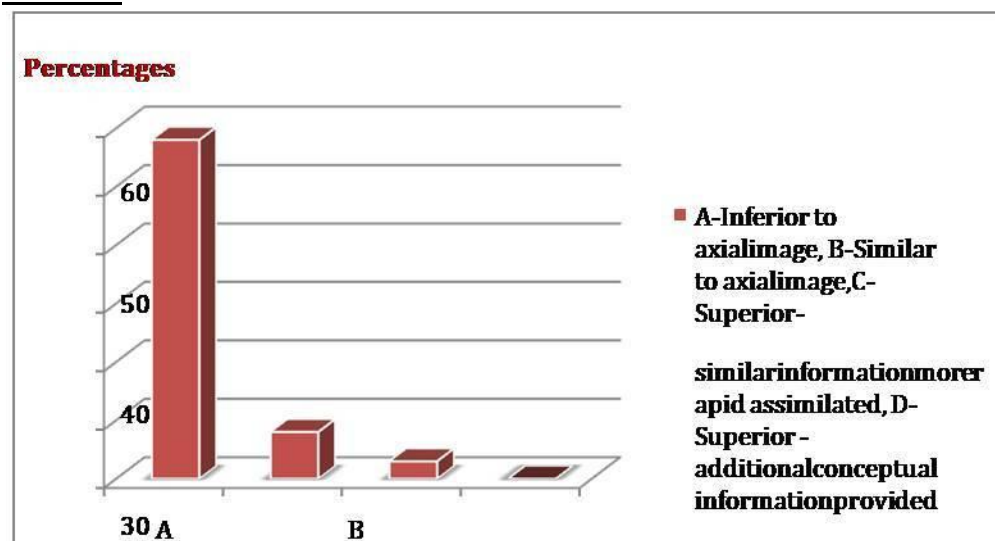


Chart – 5: Naso-Orbito-Ethmoid Fractures.



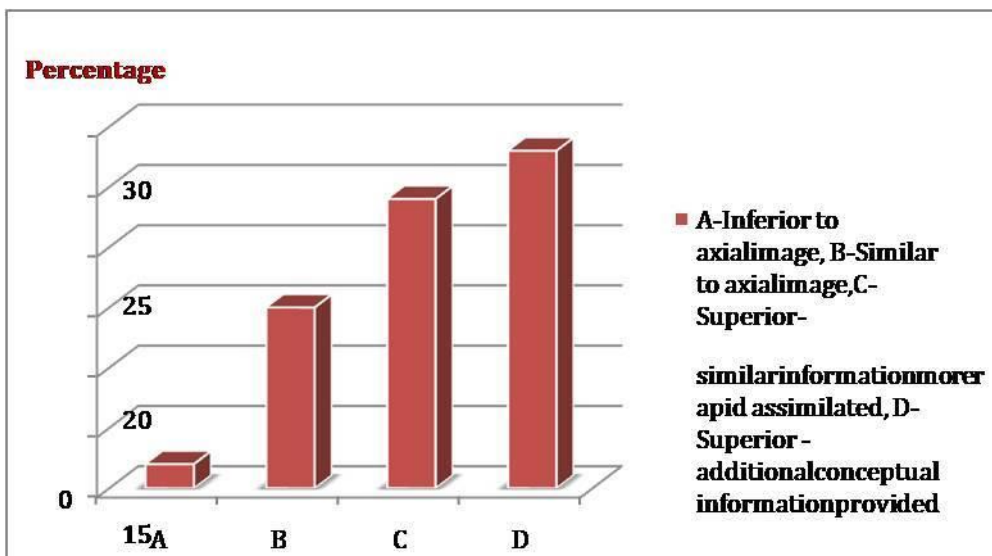
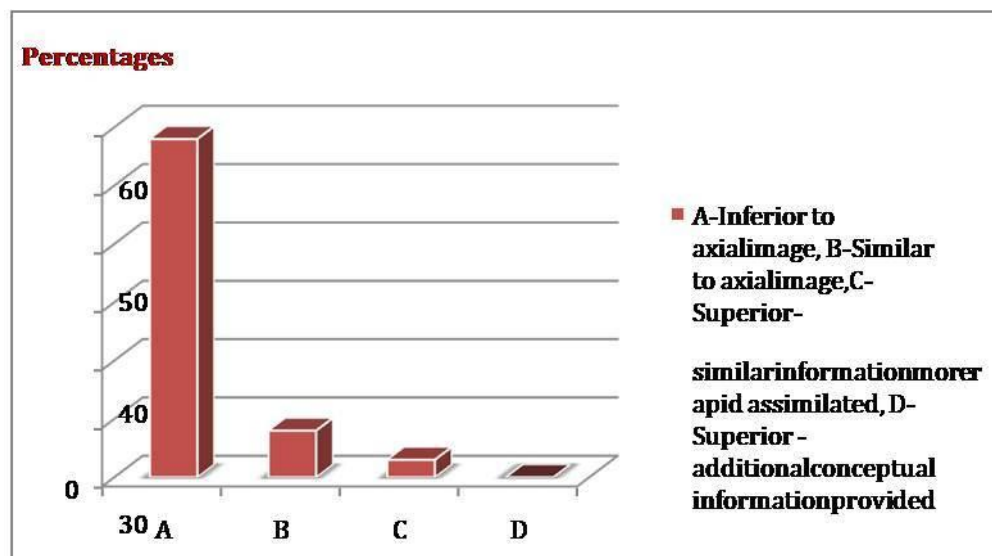
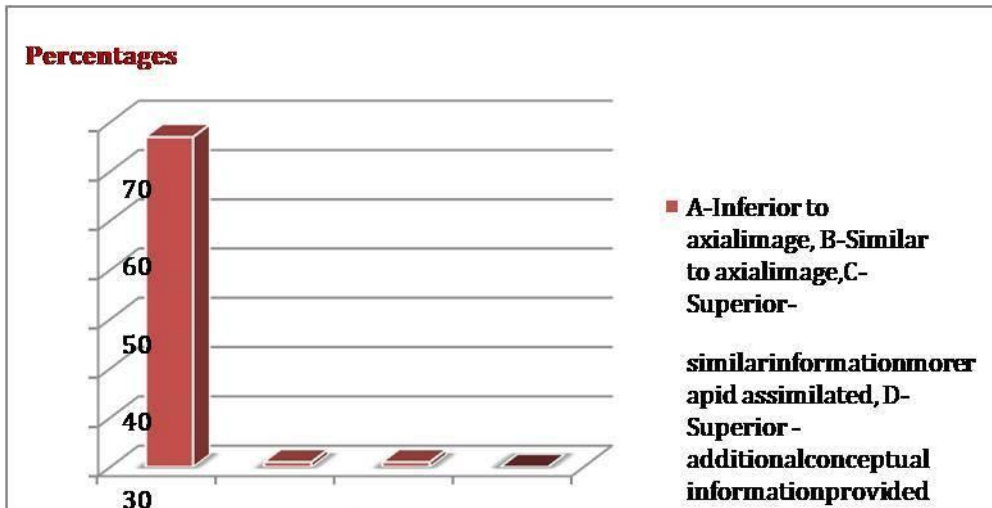
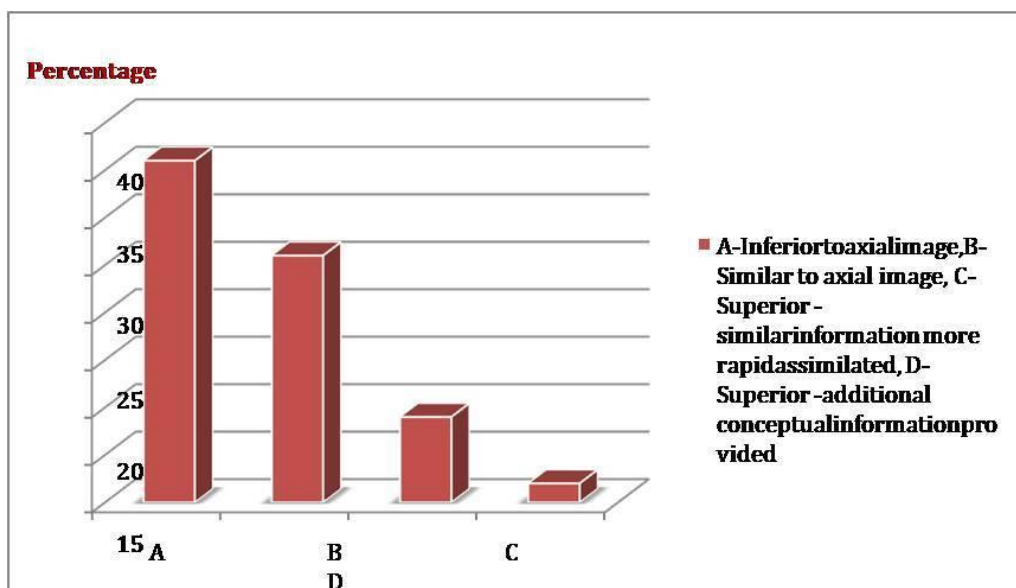
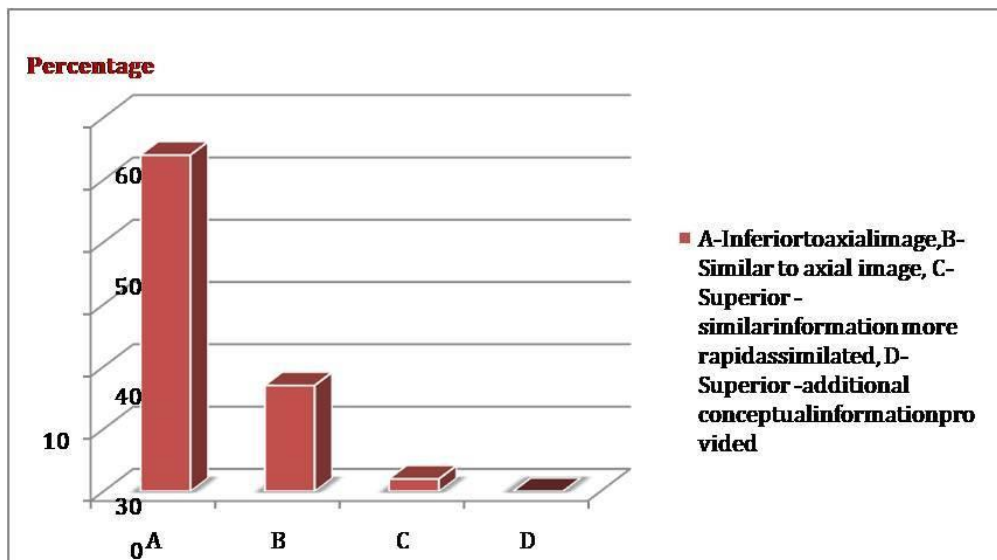
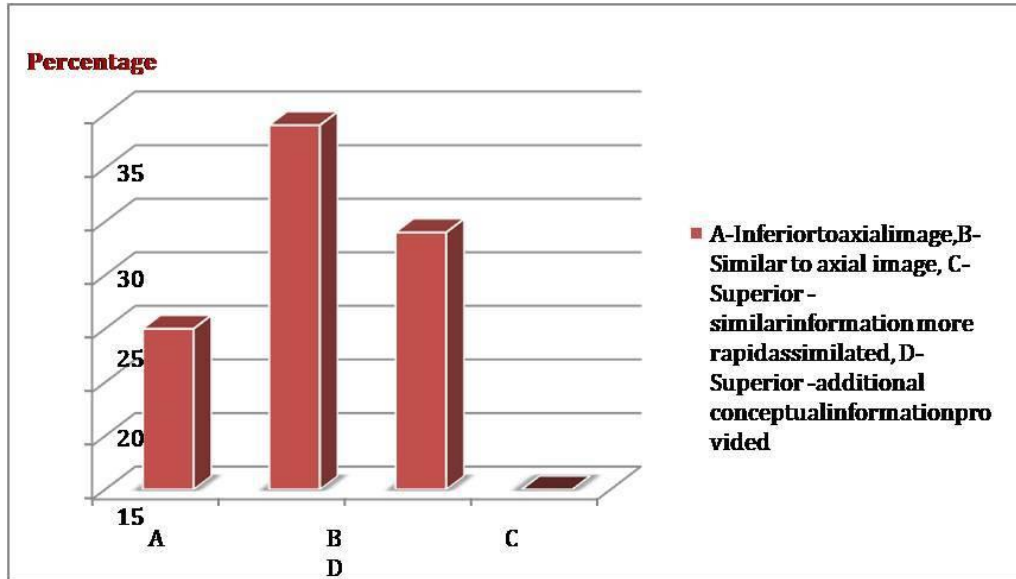


Chart – 6: Fractures in Maxilla.



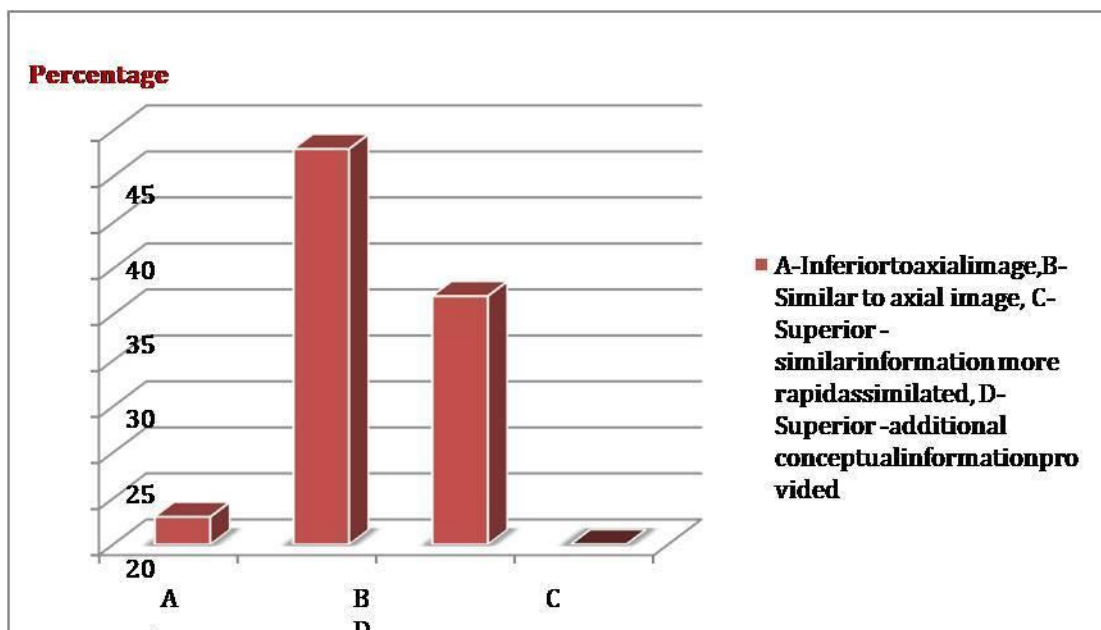
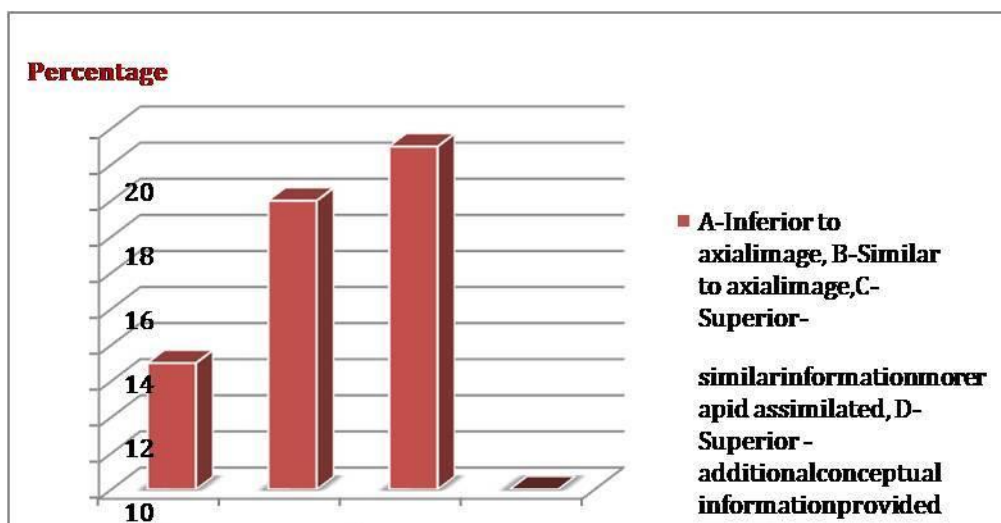
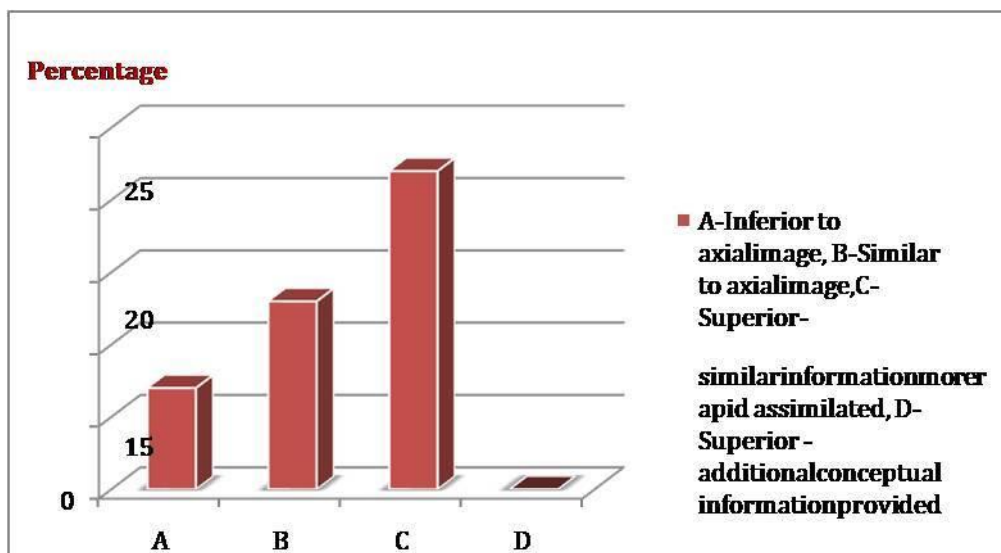


Chart – 7: Fractures in Mandible.



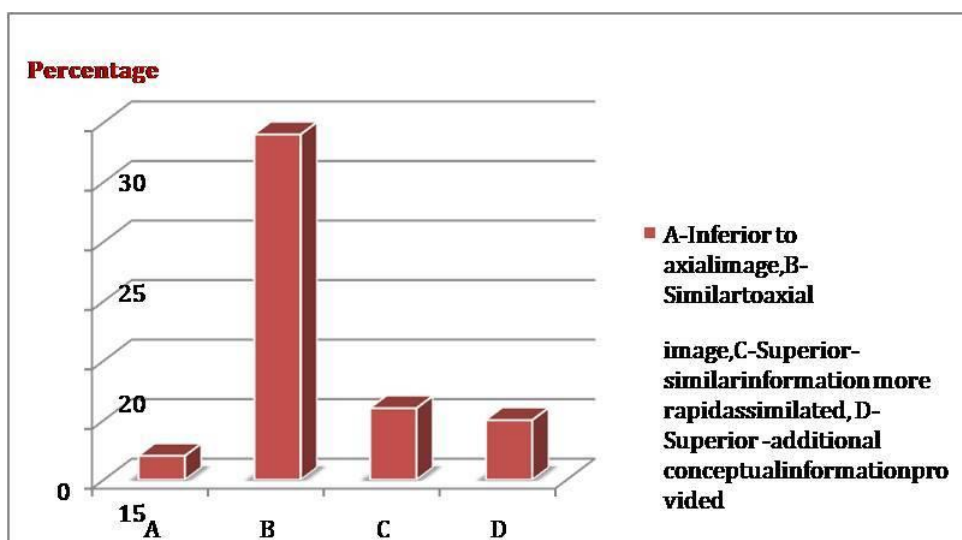
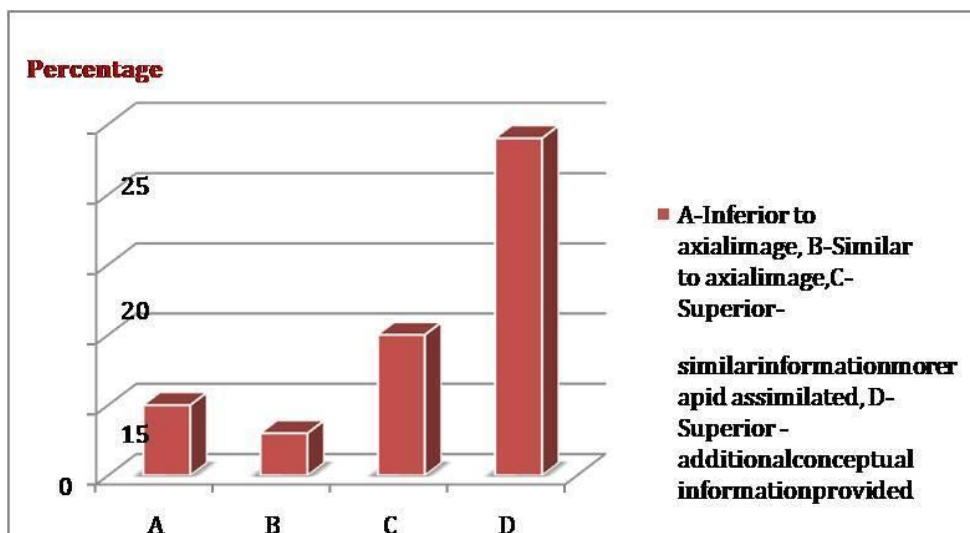


Chart - 8: Distribution of fractures detected in the maxillofacial region.

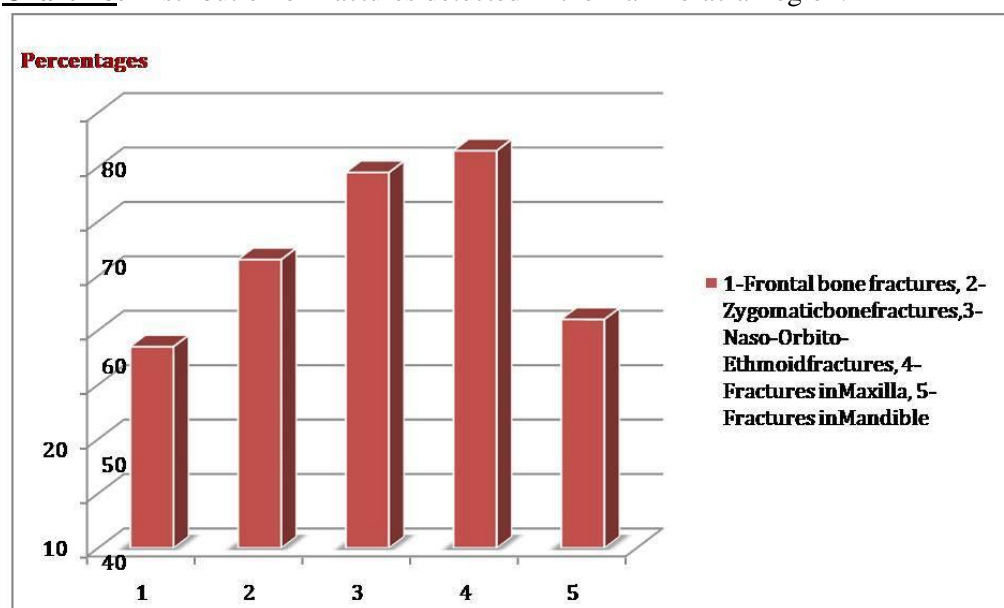


Chart – 9: Associated findings.

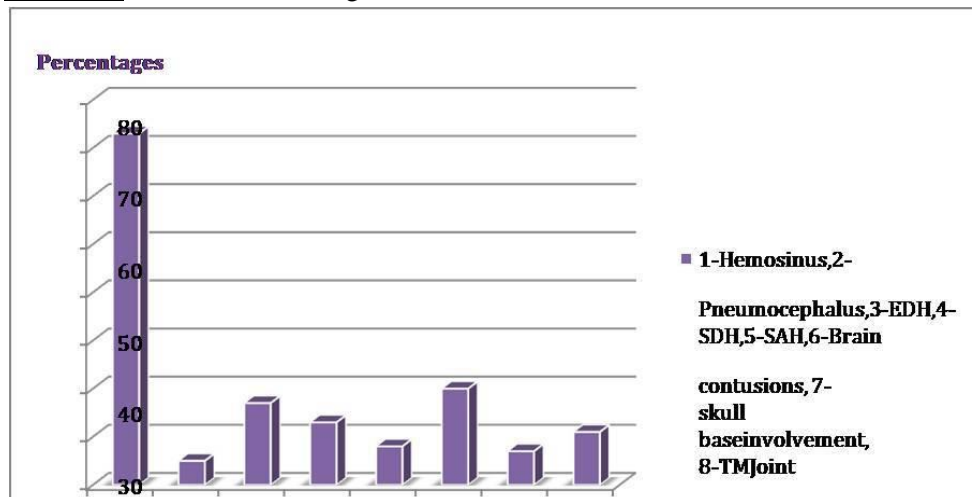


Chart - 10: Orbital injury classified according to the wall involved.

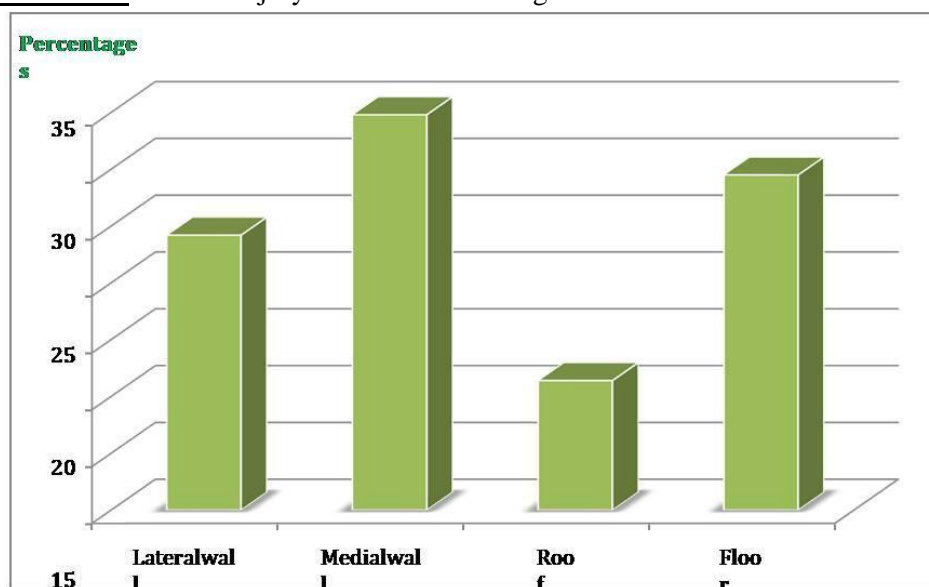
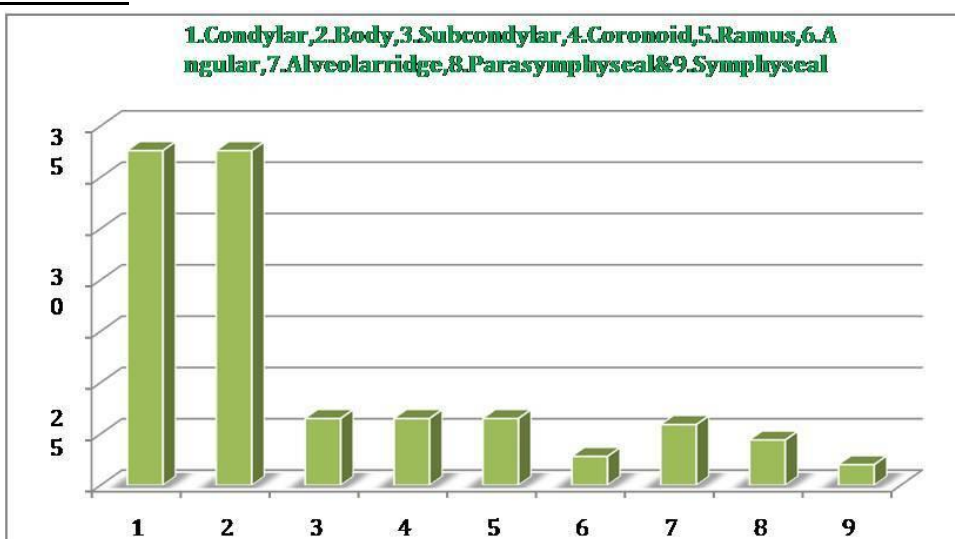
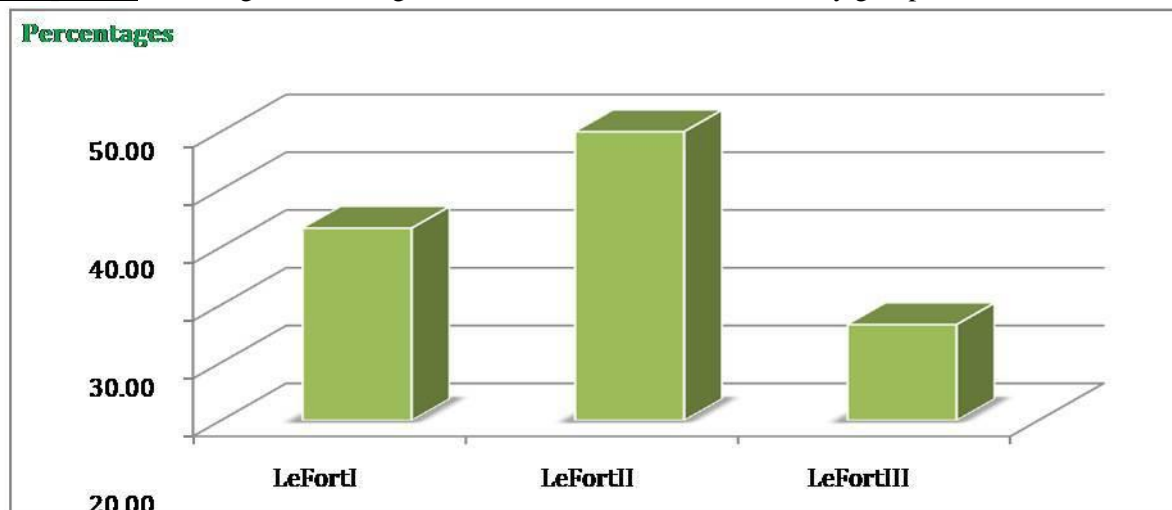


Chart - 11: Classification of mandibular fractures.



Graph - 12: Bar diagram showing the lefort lines identified in the study group.



The most common mode of injury in patients presented with maxillofacial trauma was road traffic accidents, comprising 81% of cases. Fall from height and assault were the other causes, comprising of 13 and 6% respectively as per **Chart - 2**.

Assessment of 3D images to describe the advantages in detection, extent, and displacement of fractures were as per **Chart - 3A, 3B, 3C**. 3D against Axial-detection as per **Chart - 3A**.

Frontal bone fracture detection, and displacements were seen better on 3D images in more percentage of patients. However, their extensions, especially into the posterior wall of the sinus or roof of the orbit were not adequately visualized on the 3D images. Coronal images were found to be similar to axial images in the detection of fractures in frontal bones (**Chart - 3A, 3B, 3C, 3D**).

Assessment of 3D images to describe the advantages in detection, extent, and displacement of fractures 3D against axial-detection (**Chart - 4A**).

Chart - 4A, 4B, 4C, 4D images were found to be similar or better for the detection and description of the extent in most patients with zygomatic bone fractures. In the assessment of displacement, it was found to be superior to axial images in most patients. Coronal images were

similar to axial images in the detection of zygomatic bone fractures.

Assessment of 3D images to describe the advantages in detection, extent, and displacement of fractures were as per **Chart - 5A, 5B, 5C**.

The 3D images were found to be inferior in the assessment of detection, extent, and displacement of fractures in the naso-orbital-ethmoid region when compared with axial images in most patients. Coronal images were superior to axial images in the detection of fractures in the region especially in the floor and medial wall of the orbit (**Chart - 5A, 5B, 5C, 5D**).

Assessment of 3D images to describe the advantages in detection, extent, and displacement of fractures were as per **Chart - 6A, 6B, 6C**.

3D images were superior in the detection of fractures in the maxilla especially with the involvement of the anterior wall of the sinus. However, the extent of involvement and its displacement were better seen on axial images. Coronal images were similar or better than axial images in the detection of fractures in the maxilla of most patients (**Chart - 6A, 6B, 6C, 6D**).

Assessment of 3D images to describe the advantages in detection, extent, and displacement of fractures were as per **Chart - 7A, 7B, 7C**.

The detection and extent of involvement assessed by 3D and axial images were similar in most patients with mandibular fractures. However, there was a definite advantage in the assessment of displacement of fracture fragments with the use of 3D images. Coronal images were similar to axial images in the detection of mandibular fractures (**Chart - 7A, 7B, 7C, 7D**).

The pterygoid plates were noted to be involved in 9 patients (9%). Sphenoid wings were involved in 11 patients. The calvarial bones, temporal and parietal bones were noted to be involved in 13 (13%) and 3 (3%) patients respectively. The maxilla, especially the walls of its sinus was noted to be the most commonly involved bone with 73% of patients having a fracture in this bone. The naso-orbit-ethmoid region was the next commonly affected region with fractures detected in 69% of patients. Zygomatic bone and mandible fractures were detected in 53 and 42% of patients. Frontal bone fractures were less common in the five regions of the face studied with 37% of patients detected to have fractures in that region (**Chart - 8**).

Hemosinus was the most common finding in patients who presented with facial trauma; it was seen in 73 patients. Brain contusions and EDH were the next commonest findings seen in 20 and 17 patients respectively. SDH was seen in 13 patients. SAH was seen in 8 patients. Skull base involvement, pneumocephalus, and TM Joint involvement were seen in 7, 5, and 11 patients respectively (**Chart - 9**).

Orbital injury classified according to the wall involved was as per **Chart – 10**. Classification of mandibular fractures was as per **Chart – 11**. Le Fort lines identified in the study group was as per **Chart – 12**.

Discussion

Maxillofacial trauma presents as isolated injuries or part of poly trauma and is clinically important as the disruption of soft tissue and bones of the face cause facial asymmetry and disfigurement

which cause emotional and cosmetic concerns and the region is also associated with several important functions of daily living [9]. Plain radiographs have been the initial modality of imaging in these patients. But they can be inadequate due to the superimposition of bony structures. Despite a higher radiation dosage compared to conventional radiography, CT is the imaging modality of choice to display the multiplicity of fragments, the degree of rotation and displacement, or any skull base involvement [10]. Dolan KD, et al. compared the clinical utility of CT with plain radiography and proved the superiority of CT in the diagnosis and classification of all fractures. Multi slice CT is a significant advance in the technology of x-ray CT, and the latest technological advance in CT imaging, resulting in the opportunity to greatly increase the speed of data acquisition and reconstruction. It has been demonstrated that multi slice CT can obtain a greater range of anatomic coverage during the scan. Continuous data acquisition and archiving occur as the entire volume of interest are scanned. Consequently, it is possible to scan rapidly a large volume of interest with high image quality, thin sections, and a low artifact rating in a short time, thereby dramatically reducing respiratory motion problems [11]. This study included 100 patients who had a history of maxillofacial injury and were found to have fractures involving the facial bones. The study included the evaluation of these patients with a 6 Slice MDCT scanner. The axial images generated were supplemented by their construction of 3D volume-rendered images as well as coronal multi planar reformatted images. The study population consisted of patients in the age group of 11 to 65 years. Most patients belonged to the 31 – 40 and 21 – 30 age groups with 27 and 26 patients respectively. This study also showed a male preponderance accounting for 89% of the case load. The most common mode of injury in patients presented with maxillofacial trauma was road traffic accidents, comprising 81% of cases. Fall from height and assault were the other causes, comprising 13 and 6% respectively [12]. Many authors reported that road traffic accidents were the most frequent

cause of facial fractures. Although some authors reported that assault (fighting) was the most common cause. RTA was found to be the most common cause of facial fractures in this study as well. Fall from height and assault being other causes of maxillofacial fractures in this study is also consistent with other similar studies mentioned. Because of social, cultural, and environmental factors, the causes of maxillofacial fractures vary [13]. In the assessment of frontal bone fractures, detection and displacements were seen better on 3D images in more percentage of patients. However, their extensions, especially into the posterior wall of the sinus or roof of the orbit were not adequately visualized on the 3D images. This is due to the overlap of the bony anterior wall of the sinus restricting visualization. Coronal images were found to be similar to axial images in the detection of fractures in the frontal bone. 3D images were found to be similar or better for the detection and description of extent in most patients with zygomatic bone fractures. In the assessment of displacement, it was found to be superior to axial images in most patients [14]. Coronal images were similar to axial images in the detection of zygomatic bone fractures. The 3D images were found to be inferior in the assessment of detection, extent, and displacement of fractures in the naso-orbit-ethmoid region when compared with axial images in most patients [15]. Fishman EK, et al. Coronal images were superior to axial images in the detection of fractures in the region especially in the floor and medial wall of the orbit. 3D images were superior in the detection of fractures in the maxilla especially with the involvement of the anterior wall of the sinus. However, the extent of involvement and its displacement were better seen on axial images. Coronal images were similar or better than axial images in the detection of fractures in the maxilla of most patients [16]. Flohr T, et al. found that 3D reconstructed CT scans were interpreted more rapidly and more accurately and that 3D CT was more accurate at assessing zygomatic fractures but was inferior to axial images for evaluating orbital fractures. Other studies have also described 3D CT as being most useful for

imaging comminuted fractures of the middle third of the face and the zygomatic 0-maxillary complex [17]. Fox LA, et al. demonstrated that these 3D CT scans altered or canceled surgical procedures, particularly in case-orbit-ethmoid fractures. These observations indicate that 3D scans enable clinicians to better assess the localization of bone fragments and their direction of displacement. Three-dimensional imaging is not indicated, however, for small fractures of the orbital floor or isolated fractures of the maxillary wall, in which the fracture is limited to one plane. Here, examining 3D scans alone can give false-negative results [18]. Coronal images were similar to axial images in the detection of mandibular fractures. Many studies have noted that 3D reconstructed images are helpful in the valuation of fracture comminution, displacement components, and complex fractures involving multiple planes [19]. The extent of comminuted fractures is better demonstrated on 3D-CT, where the size, shape, and displacement of individual fragments are revealed. The combination of multi slice CT and 3D volume rendering techniques allows several improvements in imaging interpretation. In this study as well it was seen that the 3D reconstructions were helpful in the evaluation of comminutive fractures, displacement components, and complex fractures involving multiple planes. Hemosinus was the most common associated finding in the patients who presented with facial trauma. It was seen in 73 patients (73%) [20]. The incidence of intracranial bleed and skull base involvement was much less. Mandibular fractures were least commonly associated with Hemosinus, intracranial bleed, and skull base involvement. The TM Joint was seen to be more commonly involved in association with mandibular fracture. The type 2 frontal bone fractures were more commonly seen in this study 11 (29.7%) times. Type 3 is the next common type occurring 10 (27.1%) times. Type 1 and type 4 fractures were seen six times (16.4%). Type 5 was the least common injury seen four times (10.2%). Similar results were also documented by Orbital floor was seen to be involved 39 times (29.5%). The lateral wall and roof were seen involved 32 and

15 times respectively [21]. This is consistent with studies of orbital fractures where the floor and the medial wall were commonly involved. The mandibular injuries were most common in the condyle and the body of the mandible. Of the 74 fractures that were detected in the mandible, 24 were noted in the condyle and body each constituting 32.6% each of the total fractures [22]. Fractures in the subcondylar region, the coronoid process, and the ramus were detected five times each (6.5%). Alveolar ridge fractures were noted four times (5.9%). Parasymphyseal fractures were noted three times (4.4%). Angular and symphyseal fractures were each noted twice. A combination of Le Fort I & II and Le Fort II & III fracture lines was found in 2 patients each. A combination of Le Fort I and Le Fort III lines or Le Fort I, Le Fort II, and Le Fort III fracture lines were not seen in any of the patients [23, 24].

Conclusion

MDCT is an accurate, non-invasive technique for the evaluation of patients with maxillofacial injuries. In the setting of accurate trauma, MDCT has the advantage of shorter scan time and is increasingly available. MPR and 3D VR images help better evaluation of fractures detected on axial images. The CT-based MPR and 3D reconstructed images, together with recent developments in computer graphics, enabled the radiologist to visualize and manipulate volumetric data quickly, permitting ready application of advanced imaging to the maxillofacial region. This is useful for the evaluation of maxillofacial fractures, especially when the surgeons can easily receive the 3D data from a work station to the operating room simultaneously by a network connection, and developing a 3D real-time model. Familiarity with the normal anatomy and the common pattern of facial fractures will aid the radiologist in providing an accurate and detailed analysis of facial fractures. This study demonstrates the valuable role of MDCT in the evaluation of maxillofacial fractures. The advantages of 3D images in the assessment of facial trauma could be described especially in the mandible and

zygomatic bone. The easier detection of fractures in the frontal and maxillary bones, as well as their displacement in patients with complex mid-facial fractures, could be described. 3D images were better in the identification of Le Fort fracture lines.

References

1. Adekeye EO. The pattern of fractures of the facial skeleton in Kaduna, Nigeria: a survey of 1,447 cases. *Oral Surg Oral Med Oral Pathol.*, 1980; 49: 491-5.
2. Adi M, Ogden GR, Chisholm DM. An analysis of mandibular fractures in Dundee, Scotland (1977-1985). *Br J Oral Maxillofacial Surgery*, 1990; 28:194-9.
3. AJ, Benovitz JD. Naso ethmoid complex fractures. *Otolaryngo Clin North Am.*, 1976; 9: 518-38.
4. Alder ME, Deahl T, Matteson SR. Clinical usefulness of two dimensional reformatted and three-dimensional rendered computerized tomographic images: literature review and a survey of surgeons opinions. *J Oral Maxillofac Surg.*, 1995; 53: 375-86.
5. Bagheri SC, Holmgren E, Kademani D, Hommer L, Bell RB, Potter BE, et al. Comparison of the severity of bilateral Le Fort injuries in isolated mid-facial trauma. *Oral Maxillofacial Surgery*, 2005; 63: 1123-9.
6. Ball JB. Direct oblique wall CT of orbital wall fractures. *AJR*, 1987; 148: 601-607.
7. Banowitz JD, Duvall AJ. Zygomatic fractures. *Otolaryngol Clin North Am.*, 1975; 9: 499-506.
8. Cavalcanti MGP, Haller JW, Vannier MW. Three-dimensional computed tomography landmark measurement in craniofacial surgical planning: experimental validation in vitro. *J Oral Maxillofac Surg.*, 1999; 57: 690-4.
9. Delbalso AM. *Maxillofacial imaging*. Philadelphia, PA, Saunders. 1990, p. 35-37.
10. Dolan KD, Jacoby CD. *Facial Fractures*.

- Semin Roentgenol., 1978; 13: 37-51.
11. Donnelly LF, Frush PD, Nelson RC. Multi slice helical CT to facilitate combined CT of the neck, chest, abdomen, and pelvis in children. *Am J Roentgenol.*, 2000; 174: 1620-2.
 12. Dos Santos DT, Costa e Silve AP, Vannier MW, Cavalcanti MG. Validity of multi slice computerized tomography for diagnosis of maxillofacial fractures using an independent workstation. *Oral Sur Oral Med Oral Path Oral Radio Endod.*, 2004; 98: 715-720.
 13. Ellis E, Moos KF, El-Atar A. Ten years of mandibular fractures: an analysis of 2137 cases. *Oral Surg Oral Med Oral Path.*, 1985; 59: 120-9.
 14. Ellis E, El-attar A. Ten years of mandibular fractures an analysis. *Oral Surgery Oral Medicine Oral pathology*, 1985; 59: 120-129.
 15. Fishman EK, Jeffrey RB. *Spiral CT: Principles, Techniques, and Clinical Applications (Ed 2)*. Philadelphia, PA, Lippincott-Raven, 1988, ppxv, 431.
 16. Flohr T, Stierstorfer K, Bruder H, Simon J, Polacin A, Schaller S. Image reconstruction and image quality evaluation for a 16-slice CT scanner. *Med Phys.*, 2003; 30: 832-45.
 17. Fox LA, Vannier MW, West OC, Wilson AJ, Baran GA, Pilgarm TK. Diagnostic performance of CT, MPR and 3D CT imaging in maxillofacial trauma. *Comput Med Imaging Graph*, 1995; 19: 385-395.
 18. Fuchs T, Kachelrieb M, Kalender WA. Technical advances in multi slice spiral CT. *Euro J Radiology*, 2000; 36: 69-73.
 19. Gillespie KF, Isherwood I, Barker Gr, Quayle AA. Three Dimensional reformations of CT in the assessment of facial trauma. *Clin Radiology*, 1987; 38: 523-526.
 20. Gosu G. CT in the assessment of orbital trauma. *Otolaryngol Clin North Am.*, 1976; 9: 477-487.
 21. Grossman RI, Yousem DM. *Neuroradiology: The Requisites (Ed 2)*. St. Louis, MO: Mosby, 2003, p. 1-35.
 22. Hall RK, Thomas C. Ten years of traumatic injury to the face and jaw; a computer analysis. Eighth International Conference on Oral Surgery, Berlin, 1982.
 23. Haug RH, Prather J, Indersano AT. An epidemiologic survey of facial fractures and concomitant injuries. *J Oral Maxillofacial Surgery*, 1990; 48: 926-32.
 24. Hessel A, Roebuck JC, Periere KD, Poole MD. 3D computed tomography reconstruction alter management decisions of facial fractures. *Otolaryngol Head Neck Surg.*, 2004; 131: 243.