


## Case Report

# Missing mandibular third molar from line of fracture: A diagnostic dilemma

Jingade Krishnojirao Dayashankara Rao \*

Associate Professor, Dept. of Maxillofacial Surgery & Diagnostic Science, College of Dentistry ,  
Qassim University, Saudi Arabia

\*Corresponding author email: [j.rao@qu.edu.sa](mailto:j.rao@qu.edu.sa)

	International Archives of Integrated Medicine, Vol. 8, Issue 11, November, 2021.	
	Available online at <a href="http://iaimjournal.com/">http://iaimjournal.com/</a>	
	ISSN: 2394-0026 (P)	ISSN: 2394-0034 (O)
	Received on: 05-11-2021	Accepted on: 10-11-2021
	Source of support: Nil	Conflict of interest: None declared.
	Article is under creative common license CC-BY	
<b>How to cite this article:</b> Jingade Krishnojirao Dayashankara Rao. Missing mandibular third molar from line of fracture: A diagnostic dilemma. IAIM, 2021; 8(11): 87-90.		

## Abstract

Maxillofacial fractures are clinically very significant because of functional and cosmetic importance of this region. Any misdiagnosis might result in disfigurement of the face as well as malocclusion. Conventional radiography along with clinical examination plays a vital role in diagnosis of maxillofacial fractures, however, concurring nature of facial bones and the inability to visualize the extent of fracture lines especially in multiple fractures, makes plain radiography less reliable. This report presents a trauma patient with a misleading finding in the pre-operative Orthopantomogram when compared with the post-operative Orthopantomogram after open reduction and internal fixation of the associated fracture.

## Key words

Mandible fracture, Open reduction and Internal Fixation, Tooth in line of fracture, Ghost image.

## Introduction

Maxillofacial injuries, especially due to road traffic accidents, account for a large number of casualty cases worldwide. Restoration of facial aesthetics and function are of prime importance for a surgeon [1]. Identification of number and type of fracture depends on the degree of displacement, type of fracture, position of fracture and the imaging modality used [2, 3]. Now a days open reduction and internal fixation

(ORIF) using mini-plates of facial fractures has become a mainstay of treatment for maxillofacial fractures [3].

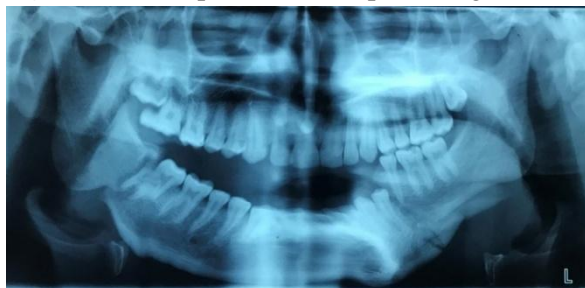In order to achieve good results preoperative evaluation using clinical and radiographic imaging is very important. In today's modern world computed tomography is considered as gold standard in diagnosis and treatment planning of facial fractures [4]. Here, we present a case of bilateral mandibular fractures which

was pre-operatively evaluated using Orthopantomogram (OPG) but this was found misleading when explored surgically and evaluated post-operatively using OPG.

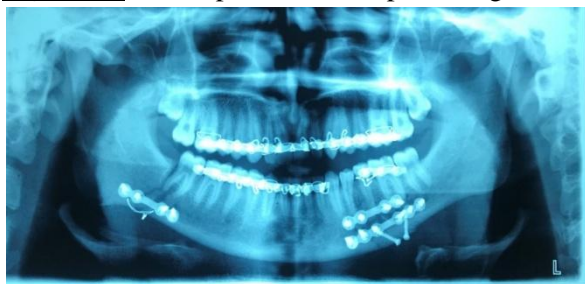
### **Case report**

A 18 years old male patient reported to Emergency Department of SGT Hospital, with alleged history of RTA. On examination, the patient presented with multiple abrasions over left side of face, tenderness over the right angle and left body region of mandible, which was associated with restricted mouth opening. OPG was the only radiographic investigation done due to patient's financial constraints, which revealed vertically displaced right angle with tooth in fracture line and comminuted left body fracture of mandible (**Figure – 1**).

**Figure - 1:** Pre-operative Orthopantomogram.



**Figure - 2:** Post-operative Orthopantomogram.

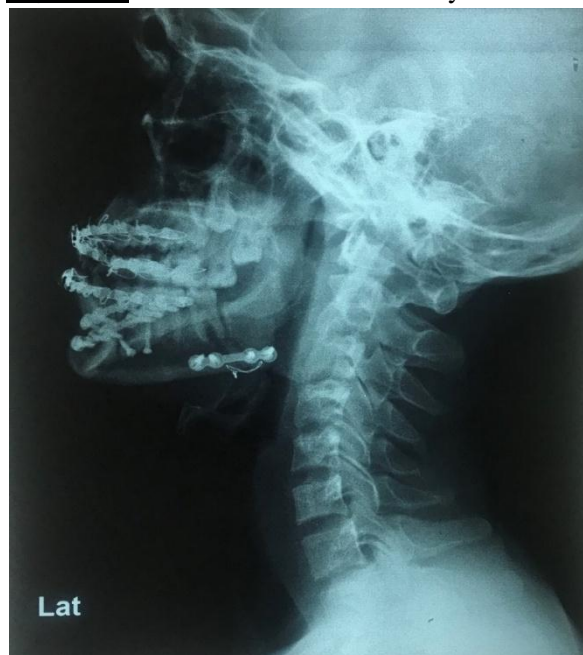

After pre-operative Clinical and Radiographic evaluation intermaxillary fixation (IMF) was done and Open Reduction and Internal Fixation (ORIF) of both fractures were planned under General Anesthesia (GA).

After achieving good occlusion using IMF right angle fracture was exposed using Submandibular approach. Keeping in mind the impacted tooth in

line of fracture, anatomical reduction of fracture was done followed by inferior border plating along with figure of eight wiring at inferior border to ensure sufficient fixation of the fracture segments. Left body fracture plating was done using both Submandibular and Transoral approach. Layer by layer closure of both surgical sites were done using 3.0 Polyglactin 910 and 5.0 nylon.

**Figure - 3:** Lateral view of neck X-ray.



Postoperative OPG (**Figure – 2**) showed adequate reduction and fixation of both fracture sites, but the tooth which was present in the line of fracture in the right angle fracture was found missing.

To rule out tooth displacement into the neck spaces lateral view of neck X-ray (**Figure – 3**) was advised and on radiographic interpretation there was no radiographic evidence of displacement of missing tooth.

Patient was on regular follow up since 1 year with good aesthetic and functional outcomes and without any other associated fracture site complication.

### **Discussion**

Facial injuries, especially bony fractures are very significant because of their functional and cosmetic importance. Accurate diagnosis of a maxillofacial fracture is very important to decide the treatment plan, analyze the mode of injury and anticipate the functional and cosmetic side effects [1]. The diagnostic modalities most commonly used for diagnosis are conventional radiography and Computed Tomography (CT).[5,6] Various studies have reported advantages of CT scan over conventional radiography due to its ability to visualize the images in three dimensions for accurate diagnosis and treatment planning of facial fractures [1, 7].

Panoramic radiographs may contain ghost images in form of single or double real images, as well as ghost images. A real image is formed when the object is located between the rotation center of the X-ray beam and the image receptor, and the image is taken carefully with high sharpness and definition keeping the object is near the central layer of the zone of focus [8, 9].

A ghost image is formed when the object is located between the x-ray source and the center of rotation. Structures situated within this region can appear as ghosts whereas structures situated elsewhere cannot do so [10].

Anatomical structures which are often seen as ghost images include the hyoid bone. The cervical Spine, inferior border of the mandible and posterior border of the ramus, the symphysis menti and the nasal turbinates [11, 12].

In the present case report, this might have happened while taking an OPG, which has led to formation of ghost image of 47 or 37 in fracture line leading to appearance of impacted third molar.

Another possible explanation for this is sagittal split of 47 at the level of cemento-enamel junction level. But this was ruled out by clinical examination of tooth, as the tooth was not mobile, and pulpal response was normal using electric pulp testing.

Since there is one more ghost image associated with 17 and 18 along with 47, hence the most possible explanation of the tooth in line of fracture is that it is because of the ghost image formation.

Because of tooth in line of fracture, we decide to go for extraoral approach instead of transoral approach. Extraoral approach has its own drawbacks which include injury to marginal mandibular branch of facial nerve, extraoral scar formation etc. [5]. This could have been avoided by preoperative CT scan after ruling out possibility of tooth in line of fracture.

## **Conclusion**

Hence, we can conclude that while evaluating mandibular fractures, enough time should be taken to interpret the radiographic images in detail, in correlation with the clinical examination findings. In case of doubt patient should be advised 3-Dimensional scans to rule out any missing findings and for formulation of appropriate diagnosis and proper execution of treatment plan.

## **References**

1. Shah S, Uppal SK, Mittal RK, Garg R, Sagar K, Dhawan R. Diagnostic tools in maxillofacial fractures: Is there really a need of three-dimensional computed tomography? *Indian J Plast Surg.*, 2016; 49(2): 225-233.
2. Ersan N, Ilgüy M. Diagnosis of unusual mandibular split fracture with cone-beam computed tomography. *J Oral Maxillofac Radiol.*, 2015; 3: 67-9.
3. Saheeb BD. Influence of positions on the incidence and severity of maxillofacial injuries in vehicular crashes [corrected]. *West Afr J Med.*, 2003; 22: 146-9. Tanrikulu R, Erol B. Comparison of computed tomography with conventional radiography for midfacial fractures. *Dentomaxillofac radiol.* 2001;30(3):141-6.

4. Tanrikulu R, Erol B. Comparison of computed tomography with conventional radiography for midfacial fractures. *Dentomaxillofac Radiol.*, 2001 May; 30(3): 141-6.
5. Mehta N, Butala P, Bernstein MP. The imaging of maxillofacial trauma and its pertinence to surgical intervention. *Radiolclin North AM.*, 2012; 50(1): 43-57.
6. Smith H, Peek ASA, Nesheim D, Nish A, et al. clinical diagnosis and characteristics of facial fracture at midwestern level, trauma center. *Journal of Trauma Nursing*, 2012; 19: 57-65.
7. Goel, A. Comparative study of clinical manifestation, plain film radiography and computed tomography for diagnosis of maxillofacial trauma. *Modern Plastic Surgery*, 2015; 05: 47-49.
8. Reuben AD, Watt-smith SR, Dobson D, Golding SJ. A comparative study of evaluation of radiographs, CT and 3D Reformatted CT in facial trauma: What is the role of 3d? *Br J Radiol.*, 2005; 78: 198-201.
9. Markowitz BL, Sinow JD, Kawamoto HK,, et al. Prospective comparison of axial computed tomography and standard and panoramic radiographs in the diagnosis of mandibular fractures. *Ann Plastsurg.*, 1999; 42: 163-9.
10. Klenk G, Kovacs A. Do we need three-dimensional computed tomography in maxillofacial surgery? *J Craniofac surg.*, 2004; 15: 842-50.
11. Mayer JS, Wainwright DJ, Yeakley JW, Lee KF, Harris JH Jr., Kulkarni M. The role of three-dimensional computed tomography in the management of maxillofacial trauma. *J Trauma*, 1988; 28: 1043-53.
12. Michael J. Reiter, Ryan B. Schwope, Jared M. Thepostoperative CT of the midfacial skeleton after trauma: review of normal appearances and common complications. *American Journal of Roentgenology*, 2017; 209(4): 238-248.