

**Original Research Article**


# A study of clinical profile and treatment outcomes in CNS tuberculoma

**E.A. Ashok Kumar<sup>1\*</sup>, Srirangam Ramya<sup>2</sup>, Sai Mounika Neelamraju<sup>3</sup>**

<sup>1</sup>Professor, <sup>2,3</sup>Post graduate

Department of General Medicine, Malla Reddy Institute of Medical Sciences, Hyderabad, Telangana, India

\*Corresponding author email: [ashokedla@gmail.com](mailto:ashokedla@gmail.com)

	International Archives of Integrated Medicine, Vol. 9, Issue 9, September, 2022.	
	Available online at <a href="http://iaimjournal.com/">http://iaimjournal.com/</a>	
	ISSN: 2394-0026 (P)	ISSN: 2394-0034 (O)
	Received on: 1-9-2022	Accepted on: 10-9-2022
	Source of support: Nil	Conflict of interest: None declared.
	Article is under creative common license CC-BY	
<b>How to cite this article:</b> E.A. Ashok Kumar, Srirangam Ramya, Sai Mounika Neelamraju. A study of clinical profile and treatment outcomes in CNS tuberculoma. IAIM, 2022; 9(9): 21-29.		

## Abstract

Worldwide, around 10 million people fall sick every year because of Tuberculosis (TB). In India, the incidence is 2.69 million cases. Central nervous system Tuberculosis (CNS TB), which is one of the most deadly forms of tuberculosis (TB) mainly manifests as TB Meningitis followed by Tuberculoma, Tubercular abscess and other forms. CNS TB is seen in 5 to 10% of extra-pulmonary TB cases, and accounts for 1% of all TB cases and has the highest mortality. They usually present with symptoms such as headache and seizures. They may have other signs and symptoms based on the size and the location of the lesions. The advent of modern technology such as CT, MRI scans helped to diagnose early. Diagnosis is established by CT/MRI Brain, where a granulomatous lesion with/without perilesional edema is seen. MR Spectroscopy brain is indicated when the diagnosis is doubtful. Presence of lipid peak on MR Spectroscopy is diagnostic of CNS Tuberculomas. Medical management is adequate and there is no role for surgery. A course of ATT for 6 months along with corticosteroids is adequate. Addition of corticosteroids is necessary to reduce the paradoxical response; it also reduces the size of the lesion and perilesional edema. Anti epileptic drugs are not necessary. CNS Tuberculoma is curable if treated properly.

## Key words

CNS Tuberculoma, ATT (Anti-Tuberculous Treatment), Corticosteroids.

## **Introduction**

Worldwide, around 10 million people fall sick every year because of Tuberculosis (TB). TB is one of the top 10 causes of death, ranking above HIV/AIDS [1]. In India, the incidence is 2.69 million cases. Although TB usually affects the lungs, it may affect other organs through hematogenous spread. Central nervous system Tuberculosis (CNS TB), which is one of the most deadly forms of tuberculosis (TB) mainly manifests as TB Meningitis followed by Tuberculoma, Tubercular abscess and other forms [2]. CNS TB is seen in 5 to 10% of extra-pulmonary TB cases, and accounts for approximately 1% of all TB cases and has the highest mortality [3, 4].

### **CNS TB may present as**

**1)Intracranial:** Tuberculous meningitis (TBM), Tuberculous encephalopathy, Tuberculous vasculopathy, CNS tuberculoma (single or multiple), Tuberculous Brain Abscess [3, 4].  
**2)Spinal:** Pott's spine and Pott's paraplegia, Non-osseous spinal tuberculoma, Spinal meningitis [3]. CNS Tuberculoma is a major cause of intracranial space-occupying lesions [5]. In regions where TB is an endemic disease, tuberculomas account for as many as 50% of all intracranial masses [6, 7].

CNS Tuberculomas are benign, non neoplastic, well circumscribed, granulomatous intraparenchymal masses which are seen usually in the cerebral or cerebellar hemispheres and uncommonly in the brainstem or spinal cord [5, 8]. But frontal lobe is the most commonly involved with 35.3% of the patients, followed by temporal and parietal lobes at 29.4% each, and at 5.9% for the occipital lobe [9]. Tuberculomas of the brain may present with a subacute or chronic illness, lasting from weeks to months. The clinical presentation depends on the size and anatomical location of the lesions. Clinical course is usually asymptomatic in patients with scant parenchymal lesions, but if these lesions are multiple or large, patients may have symptoms such as headache, focal neurological

deficits, seizures, vomiting, hydrocephalus, meningeal irritation signs and intracranial hypertension with papilledema [10, 11, 12]. Neuroimaging studies i.e. CT scan and MRI scan with contrast enhancement and MR spectroscopy are the basis for diagnosis of CNS tuberculoma [12, 13]. Evidence of extraneural TB will aid in the diagnosis [2]. Tuberculomas have to be differentiated from other space occupying lesions such as pyogenic abscess, toxoplasmosis, sarcoidosis, hydatidosis, syphilitic gummas and primary/metastatic malignant lesions [14]. Management of CNS Tuberculomas includes treatment with 4 ATT drugs i.e. Isoniazid, Rifampicin, Pyrazinamide and Ethambutol and corticosteroids [15].

Tuberculosis remains a significant health concern in developing nations like India. Although, now, CNS Tuberculosis is rare, it can be life threatening [16]. Tuberculomas are often misdiagnosed as other space occupying lesions [17]. Therefore, prompt and correct diagnosis and an early treatment are necessary to cure. The present study is aimed at studying the clinico-radiological features of CNS Tuberculoma patients and to study the various treatment outcomes and also to review the recent literature about CNS Tuberculomas.

## **Aim and objectives**

- To study the clinical profile and imaging features in CNS Tuberculoma patients.
- To study the treatment outcomes in CNS Tuberculoma patients.

## **Materials and methods**

### **Inclusion criteria**

- All patients of either sex, above 18 years, showed signs, symptoms and imaging features consistent with CNS Tuberculomas.
- All patients who gave informed consent.

### **Exclusion criteria**

- All patients below 18 years age.
- All patients having Spinal cord Tuberculomas.

- All patients having intracranial space occupying lesions other than CNS Tuberculomas.
- All patients who refused to give consent.

### Methodology

The study was done in Department of General Medicine in Malla Reddy Institute of Medical Sciences.

**Study design:** Prospective Observational Study

**Study period:** January 2021 to July 2022

**Sample size:** 30 patients.

- The institutional ethics committee approval was taken.
- The scientific committee approval was taken.
- An informed consent of the patient was taken.
- This was a prospective observational study.

The study was undertaken in the Department of General Medicine in a tertiary care hospital.

A detailed history was taken from the patient. History included the patient's name, age, gender, occupation, address and chief complaints with duration of the illness. Past history of pulmonary or extra-pulmonary infections was taken. History of TB contacts and BCG vaccination was taken.

A detailed physical examination of all systems with special attention to the CNS was done. All routine investigations were done along with the following additional investigations: ESR, Sputum for AFB (CB NAAT), Chest X-ray, CSF analysis (CB NAAT), HIV testing, CT scan brain and MRI Brain.

### Diagnostic criteria

The diagnosis was made based on the signs and symptoms of the patient and the CT scan brain/ MRI scan brain findings. Other investigations were done where necessary.

### Management

Treatment with ATT (Isoniazid- 5 mg/kg body weight, Rifampicin- 10 mg/kg body weight, Pyrazinamide- 15-30 mg/kg body weight and

Ethambutol- 15-25 mg/kg body weight) and steroids were started. Other symptomatic treatment was given where necessary. Any adverse drug reactions during the course of treatment were noted. Patients were followed up regularly through repeated clinical examination every month for a period of 6 months.

### Results

The age of the subjects in the study group ranged from 18 to 80 years. Maximum number of patients (46.67%) was between the age group 18-27 years, which is the most productive age group.

Among subjects in the study group 16 were males and 14 were females. The most common symptom among the study subjects was headache (in 17 subjects) followed by seizures (in 11 subjects) (**Table - 1**).

**Table – 1:** Distribution of cases in relation to symptoms.

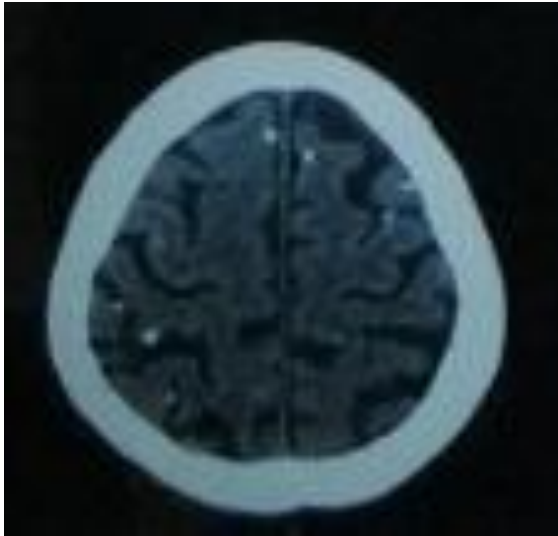
Symptom	No. of patients
Seizures	11
Headache	17
Vomiting	02
Giddiness	05
Sensory deficits	01
Motor deficits	02
Cranial nerve palsy	01

**Table – 2:** Distribution of cases in relation to part of brain involved.

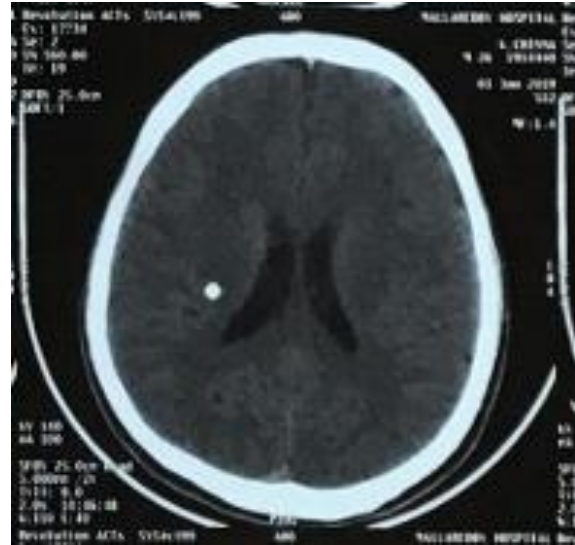Part of brain involved	No of patients
Frontal lobe ( <b>Figure - 1</b> )	09
Parietal lobe ( <b>Figure - 2</b> )	22
Temporal lobe ( <b>Figure - 3</b> )	08
Occipital lobe ( <b>Figure - 4</b> )	06
Pontomedullary junction ( <b>Fig - 5</b> )	01

Parietal lobe was the most commonly involved part of the brain, followed by frontal, temporal and occipital lobes and was involved in 22, 9, 8 and 6 patients respectively. One patient had involvement of pontomedullary junction (**Table - 2**).

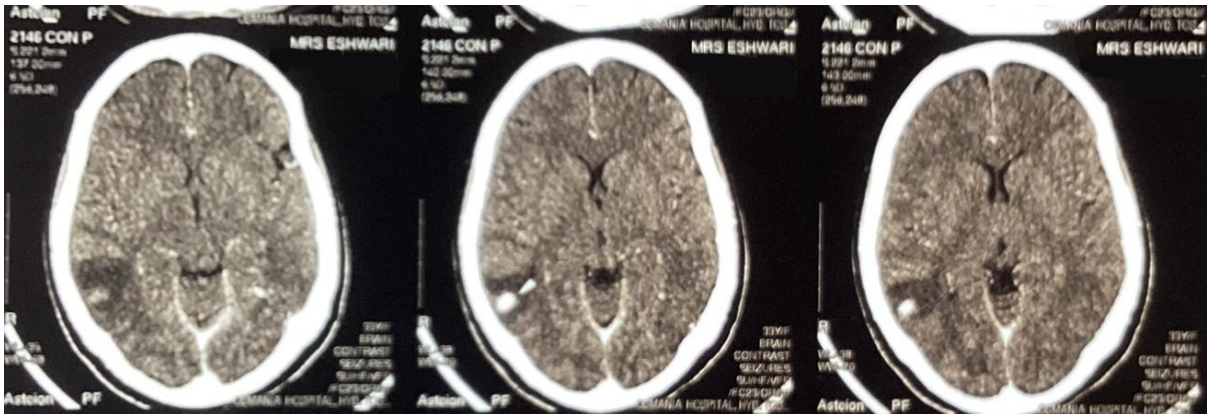
**Figure – 1:** Tuberculoma in frontal lobe.



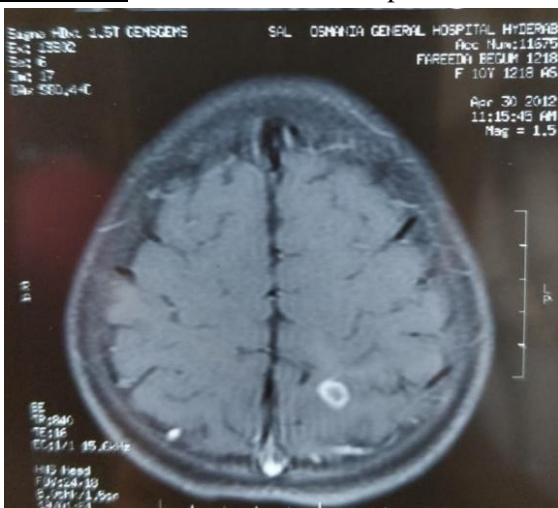
**Figure – 2:** Tuberculoma in parietal lobe.



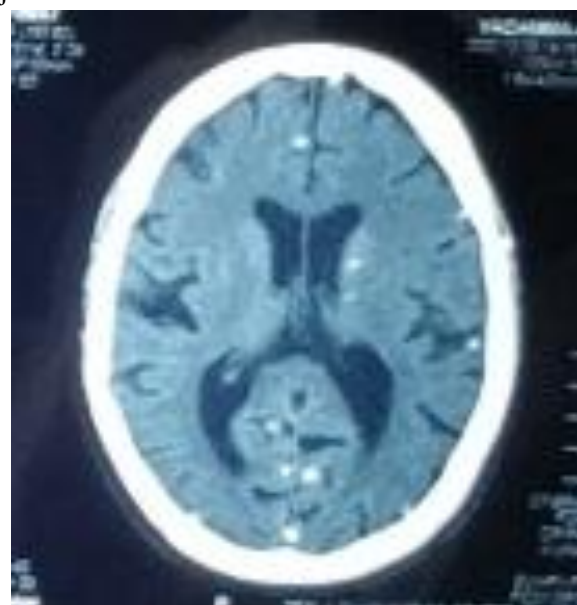
**Figure – 3:** Tuberculoma in temporal lobe.



**Figure – 4:** Tuberculoma in occipital lobe.



**Figure - 5:** Tuberculoma in ponto medullary junction.



ESR value may be normal in CNS Tuberculoma. Only 3 subjects (10%) had past history of CNS Tuberculosis. Remaining 27 subjects (90%) did not have any past history of CNS Tuberculosis.

27(90%) subjects had received BCG Vaccination and 3 subjects (10%) did not receive BCG vaccination.

2 subjects (6.66%) had associated CSVT along with CNS Tuberculoma. Tubercular abscess was present in one patient along with CNS Tuberculoma. There was no coexisting TB Meningitis in any of the patients. All the patients are non reactive for HIV I and II. Sputum AFB and CB NAAT were negative for all the patients. CSF Analysis was normal in all patients. CSF CBNAAT was negative in all patients. Tubercular abscess was present in one patient along with CNS Tuberculoma. All the 30 patients have completed the course of ATT and are symptom free now. There were no deaths.

## Discussion

Amongst the 30 patients studied, the age group varied from 18-80 years. 14 patients (46.67%) are in the age group 18-27 years and 4 patients (13.33%) are in the age group 28-37 years. Therefore 60% of the patients are below 37 years age that is, younger age group, which is more productive age group. This finding is consistent with previous studies in literature which states that CNS Tuberculomas are a disease of the young and usually present before 40 years age [4, 18, 19].

In the present study, out of 30 patients, 16 (53.33%) are male and 14 (46.66%) are female, the ratio being 8:7. E. Uma Maheswari, et al. [20] in their study revealed a male: female ratio of 1.86:1. There is a male preponderance in the study and it is consistent with the findings of the present study.

CNS Tuberculomas can have varied clinical presentations based on the location and the size of the lesions. The symptoms noticed amongst the study subjects of the present study are seizures, headache, vomiting, giddiness, sensory and motor deficits and cranial nerve palsies. Muralidhar K Katti [2] has found that the usual symptoms are headache, seizures, vomiting,

cranial nerve palsies and coma. Irfan Ahmad Shah, et al. [21] also found that headache was present in 57% of the patients. This is similar to the findings of the present study. Seizures was the 2<sup>nd</sup> most common symptom encountered and was present in 11 subjects (36.67%). Seizures were more frequently encountered amongst patients who had perilesional edema. Abdulaziz AlSemari, et al. [22] revealed that seizures occurred in 22 out of 93 patients (23.6%). These 22 patients had multiple seizure types such as partial-simple and complex, generalized, tonic and clonic seizures. In the present study, all the patients became seizure free after completion of ATT along with steroids. This is consistent with the findings in the study done by Abdulaziz AlSemari et al. [22].

The central nervous system examination was normal in 28 patients. Amongst the remaining 2 patients, one patient had monoparesis of left lower limb. The other patient had left sided hemiparesis with right sided lower motor neuron type facial palsy. This patient was also in a state of altered sensorium during presentation, the cause of which was hyponatremia. The fundoscopic examination was normal among all the patients. P.M. Udani, et al. [23] in their study revealed the presence of focal neurological deficits such as paralysis, abnormal movements and cranial nerve palsies. Constitutional symptoms were absent amongst most of these patients. In a study done by H.M. Dastur [24] in 400 patients, also, the incidence of constitutional symptoms was less. The findings of the present study are consistent with those of the above 2 studies.

Past history of CNS Tuberculomas was present in 3 patients (10%) out of 30 patients. Past history of CNS Tuberculomas was confirmed by re-assessing the previous CT/MRI Brain films. The previous CT/MRI Brain films revealed the presence of intracranial space occupying lesions (granuloma) surrounded by perilesional edema. Imaging was again repeated during this presentation to determine any progression/regression of the lesions and to look for the

presence of any perilesional edema. The 3 patients presented with seizures both previously and at present. Out of these 3 patients, 2 patients were treated with anti epileptic drugs and the cause of the intracranial space occupying lesion was not established during the previous evaluation. One patient was diagnosed as having CNS Tuberculoma during the previous evaluation and she was started on ATT, but she defaulted treatment midway due to the development of allergic reaction to ATT.

In earlier days, Radiologists and Physicians have diagnosed calcified granuloma and they thought, there was no need for treatment. And this led to the recurrence. Therefore it is important to correctly diagnose and treat even calcified granulomas. Past history of Pulmonary TB and other forms of extra-pulmonary TB was absent amongst all the patients. This is consistent with previous literature which states that not all patients with CNS TB have pulmonary TB [25, 26].

Family history of pulmonary and extra-pulmonary tuberculosis was obtained from all the patients and it was absent amongst all. History of TB contacts was absent amongst all the patients.

BCG Vaccination status was ascertained by the presence of vaccination scar and by enquiring regarding vaccination. BCG Vaccination was taken by 27 patients and not taken by 3 patients. There has been a decline in the incidence of TB Meningitis due to effective BCG vaccination. This has been reflected in the present study as none of the 30 patients had associated TB Meningitis. CNS Tuberculomas are more common among the vaccinated and TB Meningitis is more common among those who did not receive any vaccination according to previous literature [27, 28].

In the present study, 16 patients (53.33%) had multiple lesions and 14 patients (46.66%) had a solitary lesion. The proportion of the patients with multiple lesions is higher in the present study compared to previous studies. J. Vimala

and I. Dinakar, [29] reported only 5 out of 22 cases (22.7%), Mathai and Chandy [30], reported 3 out of 143 and Rao and Dinakar [31], reported only 3 out of 56 cases who had multiple lesions. In the present study, parietal lobe was the most commonly involved lobe (in 22 patients) followed by frontal, temporal and occipital lobes which were involved in 9, 8 and 6 patients respectively. One patient had involvement of pontomedullary junction along with frontal and parietal lobes and this patient presented with facial nerve palsy and hemiparesis. The findings of the present study are consistent with previous literature, which states that frontal and parietal lobes are the most commonly involved lobes [32].

Thus, 29 patients in the study had intracerebral tuberculomas and one patient had both intracerebral and brainstem tuberculoma. In a study done by Bayindir C et al. [17], 19 out of 23 patients had intracerebral tuberculomas. This is consistent with the findings of the present study. In this study, the location of tuberculomas was supratentorial in 29 patients. Tuberculomas were present in both supratentorial and infratentorial locations in one patient. This observation is consistent with the study done by Bayindir C, et al. [17], where 20 out of 23 patients had supratentorial tuberculomas. In the present study, perilesional edema was present in 17 out of 30 patients and was absent in 13 patients. One patient had an associated Tubercular abscess along with CNS Tuberculoma.

CNS Tuberculomas are usually not associated with concomitant meningitis [33]. In the present study, none of the patients had coexisting TB meningitis. Two patients in the present study had associated CSVT. According to previous literature, several pathophysiologic processes such as endothelial injury, alterations in normal blood flow and in blood coagulability explain the relation between TB and CSVT [34].

The ESR values were less than 40 in 80% of the patients and were more than 40 in only 20% of

the patients. Therefore the ESR values may or may not be raised in CNS Tuberculomas.

The chest radiograph was normal in all the patients. The sputum for AFB and CBNAAT were negative amongst all the patients. Therefore, there was no evidence of present and past pulmonary tuberculosis among the 30 patients. This is in contrast to previous literature by Thwaites GE, et al. [35] which states that presence of active pulmonary tuberculosis ranges from 30 to 50%.

CSF analysis was normal amongst all the 30 patients and CSF CBNAAT was negative. The presence of normal CSF analysis should not be taken as a reason for ruling out CNS Tuberculomas. CSF-CBNAAT are neither sensitive nor specific in the diagnosis of CNS Tuberculomas [36].

All the 30 patients were treated with ATT, steroids and other symptomatic treatment.

Corticosteroids were added for 3 months and tapered over 4 weeks. Dexamethasone was given at a dose of 5mg/day. Steroids reduce the size of the tuberculoma, perilesional edema, help in symptom control and reduce paradoxical response. None of the patients in the present study had any paradoxical response to ATT, thereby proving the beneficial role of steroids in the treatment of CNS Tuberculomas. This is consistent with a previous study done by Edward Harder, et al. [37], There was no evidence of worsening or dissemination of tuberculosis in the patients after receiving corticosteroids both in the present study and in the study done by Edward Harder, et al. [37].

Anti-epileptics were discontinued once the diagnosis was established. None of the patients had recurrence of seizures. This proves that there is no role of anti-epileptics. This is in contrast to previous studies. Abdulaziz AlSemari, et al. [38] have stated that treatment with anti epileptic drugs is necessary and that seizures tend to recur unless treated with antiepileptic drugs.

All the patients were followed up monthly till the ATT course was completed. All the patients improved within one month of treatment. All the 30 patients were cured and there was no relapse of symptoms. Thus, CNS Tuberculoma patients have a good prognosis if diagnosed promptly and treatment is initiated early. The need for regular follow up and strict compliance to the medication has to be emphasized to the patients.

## **Conclusion**

CNS Tuberculomas are an important cause of intracranial space occupying lesions and it is important to differentiate it from other causes, such as neurocysticercosis. CNS Tuberculomas are more common, Neurocysticercosis is rare. It is more common among the younger age group with a male preponderance. Headache and seizures are the most common presenting features. CNS Tuberculomas with or without perilesional edema is seen on CT/MRI Brain. Lipid peak on MR Spectroscopy is confirmatory of CNS Tuberculomas. Patients with calcified granulomas, presenting with signs and symptoms of intracranial tuberculomas should be diagnosed and treated as such. Medical management is curative of CNS tuberculomas. There is no role for surgery in CNS tuberculomas. A 6 months course of ATT given along with corticosteroids is adequate. There is no role of anti-epileptics in CNS tuberculomas. Past history of tuberculosis may/ may not be present. ESR and CSF analysis may be normal. BCG vaccination, which is a part of Revised National Tuberculosis Control Programme, helps to reduce the more serious forms of CNS Tuberculosis such as TB Meningitis. CNS Tuberculoma patients recover completely, if correctly diagnosed and treated.

## **References**

1. World Health Organization; Global Tuberculosis Report; World Health Organization; 2019.
2. Muralidhar K. Katti. Pathogenesis, diagnosis, treatment, and outcome aspects of cerebral tuberculosis. Med Sci Monit., 2004; 10(9): RA215-RA229.

3. Cherian A, Thomas SV. Central nervous system tuberculosis. *Afr Health Sci.*, 2011; 11(1): 116-127.
4. R. Bryan Rock, Michael Olin, Cristina A. Baker, Thomas W. Molitor, Phillip K. Central Nervous System Tuberculosis; Pathogenesis and Clinical Aspects. *Peterson Clin. Microbiol. Rev.*, 2008; 21(2): 243.
5. Index TB Guidelines; Guidelines on Extra-pulmonary Tuberculosis for India; In: Initiative of Central TB Division, Ministry of Health and Family Welfare, Government of India; 2016.
6. Gupta RK. Chapter on Tuberculosis and other non-Tuberculous Bacterial Granulomatous Infections; In MR imaging and spectroscopy of central nervous system infection. Gupta RK, Lufkin RB (ed): Springer US. Kluwer Academic Plenum Publishers, 2001, p. 95 -133.
7. Deepak Patkar, Jayant Narang, Rama Yanamandala, Malini Lawande, Gaurang V. Shah. Central Nervous System Tuberculosis Pathophysiology and Imaging Findings. *Neuroimaging; Clin. of North America*, 2012; 22(4): 677-705.
8. Garg RK. Tuberculosis of the central nervous system. *Postgrad Med J.*, 1999; 75(881): 133-140.
9. Velázquez G, Lara H, Reséndiz M, Aguirre D, Chávez L, Olvera JE. Tuberculomas encefálicos, informe de 31 casos en 33 años de autopsias del Hospital General de México *Patología*, 2008; 46(1): 13-9.
10. Krivoy A, Lozada VE, Arrieche WJ. Tuberculosis de Sistema Nervioso Central. Experiencia del Hospital de Niños “JM de Los Ríos”, Caracas 1990-2008. *Gac Méd Caracas*, 2009; 117: 138-45.
11. DeAngelis LM. Intracranial tuberculoma: case report and review of the literature. *Neurology*, 1981; 31: 1133-6.
12. Assefa G, Omar F, Biluts H, Abebe M. Review of the clinical computerized tomography scan and /or magnetic resonance imaging findings of intracranial tuberculoma in an Ethiopian teaching hospital. *Ethiop Med J.*, 2016; 54(3): 135 -140.
13. Ramachandran R, Muniyandi M, Iyer V, Sripriya T, Priya B, Govindarajan TG. Dilemmas in the diagnosis and treatment of intracranial tuberculomas. *J Neurol Sci.*, 2017; 381: 256-64.
14. Oncul O, Baylan O, Mutlu H, Cavuslu S, Doganci L. Tuberculous meningitis with multiple intracranial tuberculomas mimicking neurocysticercosis clinical and radiological findings. *Jpn J Infect Dis.*, 2005; 58(6): 387-389.
15. E.A. Ashok Kumar, P. Jijiya Bai. A clinical study of CNS Tuberculomas. *Int Arch Integr Med.*, 2016; 3(6): 101-106.
16. Arthur R. DeLance, Michael Safaee, Michael C. Oh, Aaron J. Clark, Gurvinder Kaur, Matthew Z. Sun, et al. Tuberculoma of the central nervous system. *J Clin Neurosci.*, 2013; 20(10): 1333-1341.
17. Bayindir Cicek, Mete Ozgur, Bilgic Bilge. Retrospective study of 23 pathologically proven cases of central nervous system tuberculomas. *Clinical Neurology and Neurosurgery*, 2006; 108(4): 353-357.
18. Arvanitakis Z, Long RL, Hershfield ES, Manfreda J, Kabani A, Kunimoto D, Power C.M. tuberculosis molecular variation in CNS infection: evidence for strain-dependent neurovirulence. *Neurology*, 1998; 50: 1827-32.
19. Kornienko VN, Pronin IN. *Diagnostic neuroradiology*. Springer Verlag, 2009.
20. E. Uma Maheswari, R. M. Bhoopathy, K. Bhanu, Heber Anandan. Clinical Spectrum of Central Nervous System Tuberculosis and the Efficacy of Revised National Tuberculosis Control Program in its Management. *J Neurosci*



- Rural Pract., 2019 Jan-Mar; 10(1): 71–77.
21. Irfan Ahmad Shah, Ravouf Parvaiz Asimi, Yuman Kawoos, Maqbool Wani, Arif Hussain Sarmast. Tuberculomas of the Brain with and without Associated Meningitis: A Cohort of 28 Cases Treated with Anti-Tuberculous Drugs at a Tertiary Care Centre. *International Journal of Contemporary Medical Research*, 2016; 3(12): 3484-3487.
  22. AlSemari A, Baz S, Alrabiah F, Al-Khairallah T, Qadi N, Kareem A, Alrajhi AA. Natural course of epilepsy concomitant with CNS tuberculomas. *Epilepsy Res.*, 2012 ; 99(1-2): 107-11.
  23. Udani PM, Parekh UC, Dastur DK. Neurological and related syndromes in CNS tuberculosis. *Clinical features and pathogenesis. J Neurol Sci.*, 1971; 14: 341–57.
  24. Dastur HM. Diagnosis and neurosurgical treatment of tuberculous disease of the CNS. *Neurosurg Rev.*, 1983; 6: 111–17.
  25. Dastur D K, Manghani D K, Udani P M. Pathology and pathogenetic mechanisms in neurotuberculosis. *Radiol Clin North Am.*, 1995; 33(4): 733-752.
  26. Bölük A, Türk Ü, TÜRK ARIBAŞ E, Kökrek Z. Intracranial tuberculoma: Clinical and MRI findings. *İnönü Üniversitesi Turgut Özal Tıp Merkezi Dergisi.*, 1998; 5(2-3): 180-184.
  27. Udani PM, Bhave SY, Tilak AM, et al. CNS tuberculosis with clinical picture modified by BCG vaccination and/or drug therapy. *J J Group Hosp Grant Med Coll.*, 1979; 24: 3.
  28. Udani PM, Parekh UC, Dasfur DK. Some neurological syndromes in CNS tuberculosis. *Neurol India*, 1972; Suppl: 63–9.
  29. J. Vimala, I. Dinakar. Tuberculomas of the brain. *Ind. J. Tub.*, 1979; Vol. XXVI, No.1: 35-37.
  30. Mathai, K.V., Chandy, J. Tuberculous infections of the nervous system. *Clin. Neurosurg.*, 1967; 14: 145-177.
  31. Rao S.B., Dinakar I. Tuberculomas of the brain. *International Surg.*, 1972; 51: 216-220.
  32. Malhotra K.P., Kulshreshtha D. Pathology of Tuberculosis of the Nervous System (Tuberculous Meningitis, Tuberculoma, Tuberculous Abscess). In: Turgut M., Akhaddar A., Turgut A., Garg R. (eds) *Tuberculosis of the Central Nervous System*. Springer, Cham., 2017.
  33. Rosenblum MK, Bilbao JM, Ang LC. Neuromuscular system, infectious disease. In: Rosai J, editor. *Rosai and Ackerman's surgical pathology*, 2, 9<sup>th</sup> ed., Mosby; 2004, p. 2490–1.
  34. Robson SC, White NW, Aronson I, Woollgar R, Goodman H, Jacobs P. Acute-phase response and the hypercoagulable state in pulmonary. *Br J Hematol*, 1996; 93(4): 943-949.
  35. Thwaites G. E., N. D. Bang, N. H. Dung, H. T. Quy, et al. The influence of HIV infection on clinical presentation, response to treatment, and outcome in adults with tuberculous meningitis. *J. Infect. Dis.*, 2005; 192: 2134–2141.
  36. Baker CA, Cartwright CP, Williams DN, Nelson SM, Peterson PK. Early detection of central nervous system tuberculosis with the gen-probe nucleic Acid amplification assay: utility in an inner city hospital. *Clin Infect Dis.*, 2002; 35 (3): 339e42.
  37. Edward Harder, M. Zuheir Al-Kawi, Peter Carney. Intracranial Tuberculoma: Conservative Management. *Intracranial Tuberculoma: Conservative Management*, 1983; 74(4): 570-576.
  38. AlSemari A, Baz S, Alrabiah F, Al-Khairallah T, Qadi N, Kareem A, Alrajhi AA. Natural course of epilepsy concomitant with CNS tuberculomas. *Epilepsy Res.*, 2012; 99(1-2): 107-11.