


## Case Report

# A case of subclavian steal syndrome

**M. Guru Mounika Reddy<sup>1\*</sup>, Satya Pratik<sup>2</sup>, Krishna Chaitanya<sup>3</sup>,  
Madhu Naveen Reddy<sup>4</sup>**

<sup>1</sup>Post Graduate, <sup>2</sup>Assistant Professor, <sup>3</sup>Associate Professor, <sup>4</sup>Assistant Professor  
Department of General Medicine, Malla Reddy Institute of Medical Sciences, Medchal, Hyderabad,  
Telangana, India

\*Corresponding author email: [mgmounika123.mgm@gmail.com](mailto:mgmounika123.mgm@gmail.com)

	International Archives of Integrated Medicine, Vol. 9, Issue 9, September, 2022.	
	Available online at <a href="http://iaimjournal.com/">http://iaimjournal.com/</a>	
	ISSN: 2394-0026 (P)	ISSN: 2394-0034 (O)
	Received on: 5-9-2022	Accepted on: 17-9-2022
	Source of support: Nil	Conflict of interest: None declared.
	Article is under creative common license CC-BY	
<b>How to cite this article:</b> M. Guru Mounika Reddy, Satya Pratik, Krishna Chaitanya, Madhu Naveen Reddy. A case of subclavian steal syndrome. IAIM, 2022; 9(9): 53-56.		

## Abstract

Subclavian steal syndrome is a relatively rare condition that results from occlusion of the subclavian artery proximal to the origin of the vertebral artery. This causes a reversal in the direction of the blood flow in the vertebral artery, leading to symptoms of vertebrobasilar insufficiency. In this article, we report a case of subclavian steal syndrome in a 55 year old male, who presented with giddiness, and variation in blood pressures in both upper limbs, was investigated with doppler and MR angiography. This article emphasises physical examination with discrepancy in pulse and blood pressure should bring attention to diagnosis of this syndrome.

## Key words

Subclavian steal syndrome, Subclavian artery, Vertebral artery, Occlusion.

## Introduction

Subclavian steal syndrome (SSS) is defined as a group of symptoms that arise from reversed blood flow in the ipsilateral vertebral artery [1].

It is often a differential diagnosis in any patient who presents with a pulse deficit or a systolic blood pressure difference of greater than 20 mmHg between the arms [2].

The subclavian steal, in the absence of other anatomical anomalies, is usually asymptomatic and often an incidental finding. Rarely, however, some patients may become symptomatic with exercise and present with transient ipsilateral arm claudication, ataxia and/or angina.

Angiography was the initial test used to screen for subclavian steal, with only high probability patients being investigated [3]. This selection bias in testing gave the false impression that SSS

was not only rare, but also symptomatic [4]. However, with the emergence of non-invasive techniques such as ultrasound in 1970 and magnetic resonance angiography (MRA) in 1992, a greater number of asymptomatic patients have been identified, reflecting the more benign nature of the condition [5, 6].

### **Case report**

A 55 year old male who is a manual labourer by occupation presented with a chief complaint of giddiness while doing work since 7 days. No history of swaying while walking. No history of tinnitus or ear discharge or ear pain, no history of weakness of upper limbs and lower limbs, seizures, loss of consciousness or cranial nerve abnormalities, tremors or incoordination of movements and bowel and bladder incontinence. Patient is able to feel clothes over his body.

He is a known hypertensive since 3 years on Tab Amlodipine 5 mg once daily. No similar complaints in the family. He smokes 10 beedis per day since 30 years.

On examination, patient was moderately built and nourished. Pulse rate 84 beats per min, regular, feeble pulse in left brachial and radial arteries and normal volume in other arteries. Blood pressure Right arm: 130/80mm Hg left arm 90/60mmHg. Both lower limbs 140/80 mmHg

Cardiovascular system was normal. Respiratory system was normal. Per abdomen examination was normal. Central nervous system examination was normal.

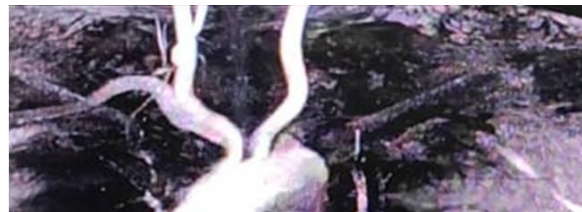As there is variation in pulse volume and blood pressure in both the upper limbs, we asked for arterial doppler of both upper limbs and MR angiography.

Arterial doppler of left upper limb showed decreased flow velocities in left subclavian, axillary, brachial, radial and ulnar arteries with

reversal of flow in left vertebral artery possibility of proximal subclavian artery stenosis.

MR angiography showed occlusion of left subclavian artery (**Figure – 1**).

**Figure – 1:** MR angiography showed occlusion of left subclavian artery.



Routine investigations like CBP, CUE, LFT, RFT, USG abdomen and pelvis, chest X-ray, ECG were normal. 2DECHO: mild concentric LVH. MRI brain – normal.

Total cholesterol - 350 mg/dl, triglycerides – 250 mg/dl, HDL – 30 mg/dl, LDL – 150 mg/dl.

### **Discussion**

Subclavian steal syndrome is relatively rare condition. Most literatures report the prevalence of subclavian steal syndrome as between 0.6% to 6.4%. Males are affected by the atherosclerotic subclavian steal phenomenon more than females by a ratio of about 2:1 [2].

Subclavian steal syndrome occurs when the subclavian artery, most commonly the left, becomes occluded proximal to the origin of the vertebral artery. In this setting, the distal subclavian artery “steals” blood from the posterior circulation of the brain by means of retrograde flow through the ipsilateral vertebral artery.

Decreased blood flow to the brain and upper extremity on the affected side results in a variety of symptoms, due to vertebrabascular insufficiency or ischemia of the affected extremity [7, 8]. Vertebrabascular insufficiency may produce light-headedness, dizziness, vertigo, ataxia, visual disturbances, motor deficits, focal seizures, confusion, aphasia, headache, presyncope,

syncope and rarely strokes. Symptoms due to ischemia of the affected extremity are less frequent and include weakness or arm claudication after exercise, paresthesias. The symptom can appear by vigorous exercise of the affected arm, and, or sudden turning of the head to the affected side [7, 8, 9].

Atherosclerosis is the most common cause (95%). Other causes of occlusion include dissecting aortic arch aneurysm, embolism, and Takayasu's arteritis.

Physical findings of subclavian steal syndrome include unilaterally decreased pulses, >20 mm Hg difference in blood pressure between the upper extremities, supraclavicular bruits, and disappearance of the radial pulse with exercise of the affected extremity.

Although subclavian steal is rare, a high index of suspicion is warranted in the presence of a suggestive history, risk factors, and physical findings. Differential diagnosis includes intracranial vascular disease, carotid artery disease, vertebral artery disease, brain tumor, and subdural hematoma [8, 9, 10].

Diagnosis of subclavian steal syndrome [8] is confirmed by carotid duplex ultrasonography, magnetic resonance or computed tomographic angiography. The Pulsed Doppler (PW) is useful in the analysis of the vertebral artery, recording information capable to indicate the presence of the subclavian steal syndrome. One of the main goals of the Doppler of vertebral arteries is the detection of reverse blood flow, indicating the phenomenon of subclavian steal [1].

Subclavian phenomenon is classified based on the degree of hemodynamic disturbances of the vertebral artery:

Stage I (Occult steal, decreased blood flow),

Stage II (partial steal, transient or partial reversal of flow), and

Stage III (Complete steal, permanent reversal of flow) [1].

The stenosis and vessel morphology can be assessed by CT or MR angiography. Time-resolved three-dimensional MRA has been described as a means of identifying reversal of vertebral artery flow [1]. Conventional angiography, although invasive, can show stenotic or occlusive lesions in the subclavian, carotid, and vertebral arteries, as well as reversal of flow in the vertebral artery.

Risk factor modification (smoking cessation and control of hypertension, diabetes, and hypercholesterolemia) is essential [8]. Invasive treatment of subclavian steal syndrome is indicated in symptomatic patients. Options include axillo-axillary bypass, carotid-subclavian bypass, and percutaneous transluminal angioplasty (PTA) of the stenotic proximal subclavian artery with stent placement [11].

## Conclusion

This case highlights the importance of subclavian steal syndrome, and high index of suspicion is warranted when there is variation in pulse and blood pressure in both upper limbs. Recognition of this syndrome is crucial, since patients can be successfully treated with PTA and stent placement or other bypass graft operations.

## References

1. Osiro S, Zurada A, Gielecki J, Shoja MM, Tubbs RS, Loukas M. A review of subclavian steal syndrome with clinical correlation. *Med Sci Monit.*, 2012; 18(5): RA57-RA63. doi:10.12659/msm.882721
2. Tan TY, Schminke U, Lien LM, Tegeler CH. Subclavian steal syndrome: can the blood pressure difference between arms predict the severity of steal? *J Neuroimaging.*, 2002; 12: 131–35.
3. Heidrich H, Bayer O. Symptomatology of the subclavian steal syndrome. *Angiology*, 1969; 20: 406–13.

4. Herring M. The subclavian steal syndrome: a review. *Am Surg.*, 1977; 43: 220–28.
5. Grossman BL, Brisman R, Wood EH. Ultrasound and the subclavian steal syndrome. *Radiology*, 1970; 94: 1–6.
6. Drutman J, Gyorke A, Davis WL, Turski PA. Evaluations of subclavian steal with two-dimensional phase-contrast and two-dimensional time-of-flight MR angiography. *Am J Neuroradiol.*, 1994; 15: 1642–45.
7. Reivich M, Holling HE, Roberts B. Reversal of blood flow through the vertebral artery and its effect on cerebral circulation. *N Engl J Med.*, 1961; 265: 878-85.
8. Harper CA, Haines JD. Subclavian steal syndrome: a report of two cases. *Postgrad Med.*, 1988; 83: 97-100.
9. Sagkaguchi S. Syncope associated with exercise. *Am J Cardiol.*, 1995; 75: 476-81.
10. Kapoor W. Evaluation and outcome of patients with syncope. *Medicine*, 1990; 69: 160-175.
11. Stipa S, Cavallaro A, Sciacca V, Mingoli A, Sterpetti A, Di Marzo L, et al. Crossover axillary bypass. Treatment of subclavian or innominate artery obstructive lesions. *Int Angiol.*, 1987; 6(4): 421-7.