



Case Report

Incidentally detected carcinoma in situ in a fibroadenoma of breast in a postmenopausal woman: A case report

Ch. Krishna Reddy¹, Kandukuri Mahesh Kumar^{1*}, T. Divyagna¹,
Chintakindi Sravan², R. Swarupa³, K. Shashi Kiran⁴

¹Assistant Professor, Malla Reddy Institute of Medical Sciences (MRIMS), Hyderabad, Telangana State, India

²Pathologist, Vijaya Diagnostic Center, Hyderabad, Telangana State, India

³Assistant Professor, Malla Reddy Medical College for Women (MRMCW), Hyderabad, Telangana State, India

⁴Pathologist, Omega Cancer Hospital, Banjara Hills, Hyderabad, Telangana State, India

*Corresponding author email: doctormaheshgoud@gmail.com

How to cite this article: Ch. Krishna Reddy, Kandukuri Mahesh Kumar, T. Divyagna, Chintakindi Sravan, R. Swarupa, K. Shashi Kiran. Incidentally detected carcinoma in situ in a fibroadenoma of breast in a postmenopausal woman: A case report. IAIM, 2015; 2(3): 197-202.

Available online at www.iaimjournal.com

Received on: 26-02-2015

Accepted on: 03-03-2015

Abstract

Fibroadenomas are the most common benign tumor of the breast. It can occur in women of any age, but the peak incidence seen in young adolescent women during the second and third decades of life. Fibroadenoma is a biphasic tumor, composed of an epithelial and a stromal component. Even though they are solitary lesions, multiple fibroadenomas can also occur especially in the older age group. Breast fibroadenomas seemed to display a wide spectrum of proliferative and non-proliferative histologic changes. Of all these changes, carcinoma arising from fibroadenoma is a rare occurrence. Here, we have presented such a rare case of carcinoma in situ arising from the long standing multiple fibroadenoma in a postmenopausal women. Clinical and radiological features are not helpful in identifying carcinoma arising from fibroadenoma. Histopathological examination of the excised specimen should be done for the confirmation of the diagnosis.

Key words

Carcinoma in situ, Fibroadenoma, Postmenopausal, Biphasic tumor.

Introduction

Fibroadenoma is one of the most common benign tumors of the breast in young women. They can occur in any age, but the peak incidence is during the second and third decades of life [1]. Fibroadenoma is a biphasic tumor, composed of an epithelial and a stromal component. Breast fibroadenomas seemed to display a wide spectrum of proliferative and non-proliferative histologic changes [1]. They are generally solitary but multiple fibroadenoma cases were also reported. Although, fibroadenoma is considered benign, there is evidence for an association with an increased risk of invasive breast cancer [2]. Moreover, the risk of developing breast cancer was found to be higher in patients with complex fibroadenoma and risk increases with age. The mean age reported for patients with carcinoma arising in fibroadenoma is in the fourth and fifth decade [2]. We have reported here, such a rare case of carcinoma in situ arising from multiple fibroadenomas.

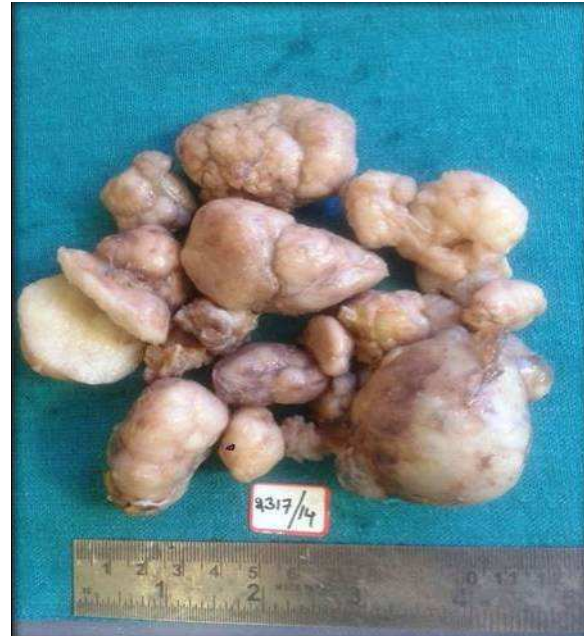Case report

A 48 years old female patient came to the hospital with complaints of mass in the left breast since 5 years. Her past history was not significant. No history of carcinoma in the family. On examination, there were multiple lumps in the left breast with largest measuring around 3 x 2 cm. Routine blood investigations were normal. Ultrasonography revealed multiple fibroadenomas. Fine needle aspiration cytology (FNAC) also showed the features of fibroadenoma. Based on these, patient offered lumpectomy and multiple swellings were sent for histopathological examination.

Gross examination showed multiple well circumscribed, well encapsulated masses ranging from 0.5 cm to 3 cm. Cut section

showed homogenous solid gray white appearance with slit like spaces. **(Photo - 1)**

Photo - 1: Multiple fibroadenomas.



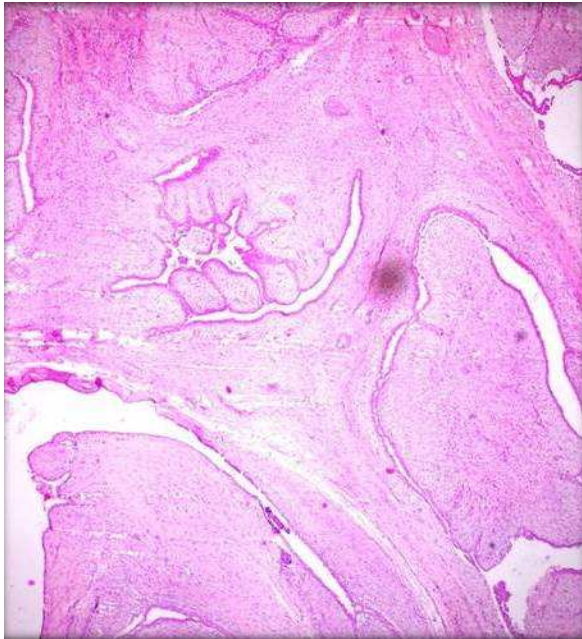
Microscopy, there were predominantly areas with histological features of fibroadenoma with inner epithelial and outer myoepithelial cells were seen, stroma was fibromyxoid. **(Photo - 2)** At foci, there were areas showing carcinoma in situ changes with closely packed cells arranged in papillary pattern with central fibrovascular core, having high nuclear cytoplasmic ratio and hyper chromatic nuclei. **(Photo - 3 and Photo - 4)** Surrounding the carcinoma, stroma was normal without any evidence of atypical cell invasion.

Discussion

Fibroadenomas are among the common benign tumors of the breast with peak incidence during second and third decade of the life. They are benign and carcinoma arising from fibroadenoma is rare. The incidence of carcinoma within fibroadenoma is reported to be 0.1–0.3%, with a peak age of occurrence at 42 to 44 years of age [3]. Cheattle and Culter

were the first to describe a carcinoma arising in a fibroadenoma [4]. Two-thirds of carcinomas within fibroadenoma are lobular, one-third is ductal or mixed ductal and lobular but lobular carcinoma in situ, and ductal carcinoma in situ has an approximately equal frequency [2, 3].

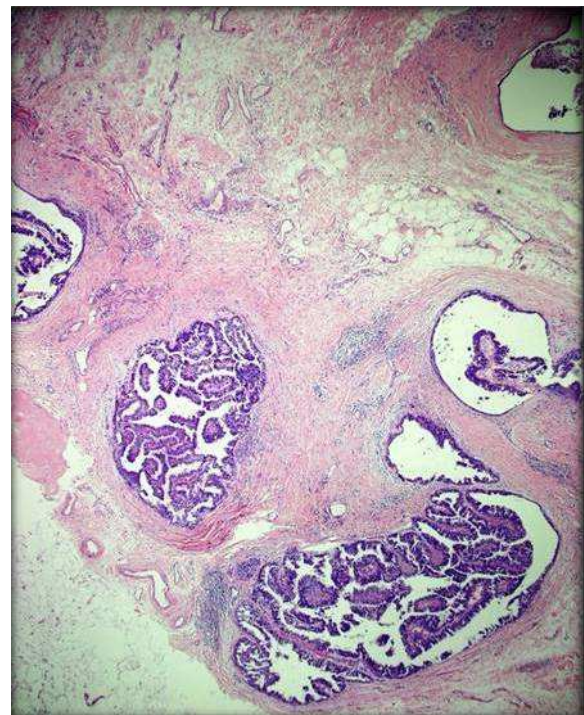
Photo - 2: Photomicrograph showing histological features of fibroadenoma.



Growth of fibroadenoma is stimulated by estrogen, progesterone, pregnancy, and lactation, at menopause, undergoes atrophic changes [2]. The epithelial component of fibroadenoma can display aberrations similar to those of the epithelial component of the normal breast. Fibroadenomas show many proliferative epithelial changes such as hyperplasia, apocrine metaplasia, cysts, squamous metaplasia, sclerosing adenosis, microglandular adenosis, papilloma, lactational changes, calcifications, and carcinoma in situ (CIS) and invasive carcinoma [1, 5]. Fibroadenomas can be classified as simple or complex based on above histological features. Complex fibroadenomas differ from simple fibroadenomas because of the presence of cysts (>3 mm), sclerosing

adenosis, epithelial calcifications, or papillary apocrine changes and have higher risk for transformation into malignancy [6]. Fibroadenomas have to be differentiated from benign phyllodes tumor, which is a close differential diagnosis, as carcinoma arising even from phyllodes tumor is also reported in the literature [7].

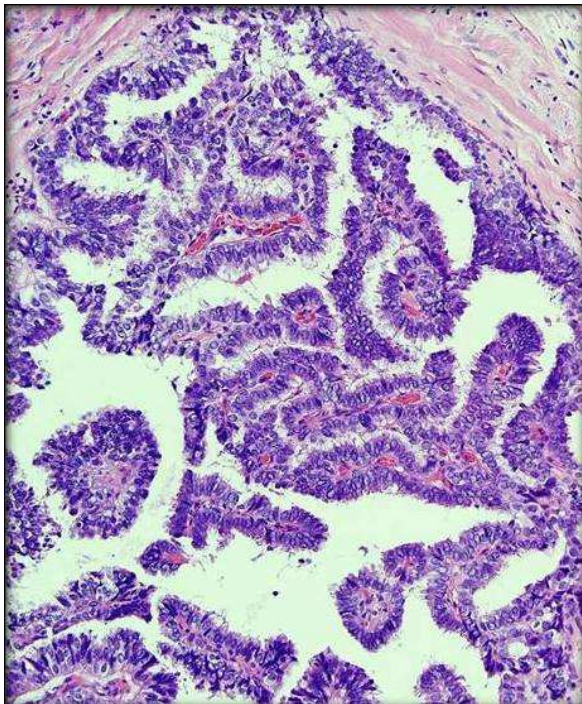
Photo - 3: Photomicrograph showing areas of in situ carcinoma changes. (10X)



Clinically, fibroadenomas present with lump in the breast, which was the presenting complaint in our case. Pre-operative diagnosis of carcinoma arising from these lesions is difficult because their presenting features are similar to those of benign fibroadenoma [8, 9]. Triple test done to evaluate breast lesions include fine needle aspiration cytology (FNAC) or core biopsy, clinical examination and radio-imaging techniques such as ultrasound and mammogram [1, 10]. In our case, triple tests were done for evaluation. Mammography may reveal an abnormality, but rarely indicates malignancy.

Ultrasound (US) findings seem more useful than mammogram or Magnetic resonance imaging findings because US examinations can be easily performed non-invasively and repeatedly [11].

Photo - 4: Photomicrograph showing papillary projections with pleomorphic cells with high nuclear cytoplasmic ratio and hyper chromatic nuclei. (40X)



The characteristic sonographic features of benign include round, slightly hypo echoic lesion with smooth borders and homogenous internal echoes and normal surrounding areas. In malignancy, the features changes to irregular shape, irregular margins, hypoechogenicity, posterior acoustic shadowing [12]. Our case, on sonography, revealed only multiple fibroadenomas. If radiological features are suggestive of malignancy, then cytological diagnosis is recommended for definitive diagnosis. FNAC is a tool that helps in guiding the surgeon to decide further management. Cytological smears in malignancy show high nucleo-cytoplasmic ratio with pleomorphism and hyper chromatic nuclei. In our case, these

features were not present hence; diagnosis was given as benign lesion. Because of limitations of FNAC for selective sampling, the confirmation is done only by the histopathological examination of the excised specimen. In our case, diagnosis was evident only on the histopathological examination (HPE).

Many criteria are followed to diagnose carcinoma in fibroadenoma. Azzopardi defined carcinomas involving fibroadenoma as arising in the adjacent breast tissue engulfing and infiltrating fibroadenoma; in the crevices of a fibroadenoma as well as in the adjacent breast tissue; and carcinoma restricted entirely or at least dominantly to a fibroadenoma [13]. The diagnostic criteria of DCIS within fibroadenoma require showing at least one of the following findings.

- Intra ductal carcinoma focus is also seen in the adjacent breast tissue.
- Intra ductal proliferative lesions within fibroadenoma show cancer-characteristic findings, e.g., epithelial necrosis [14].

The presence of a fibroadenoma in a woman with a positive family history may have greater clinical importance than fibroadenomas occurring in women with no additional risk factors the detection of a fibroadenoma. The biological behavior of a carcinoma occurring in a fibroadenoma is no different from that of breast carcinoma unrelated to fibroadenoma.

Definitive treatment consists of surgery with or without radio or chemotherapy. Surgical management depends on the stage at presentation and the presence of axillary or distant metastasis [11]. Excision with breast conservative surgery is done for in situ carcinoma arising from the fibroadenoma. Chemotherapy and radiotherapy is rarely required but advised in advanced cases to



prevent recurrence [15]. Prognosis is good in cases of early detection.

Conclusion

Though fibroadenomas are common benign tumors, carcinoma in a fibroadenoma is a rare occurrence. Carcinoma are common in complex fibroadenoma and in patients with family history of the breast carcinoma and risk increases as age increases, hence all cases presenting in old age and positive family history are screened for any possibility of carcinoma. In present case radiology and cytology revealed only multiple fibroadenoma but carcinoma was detected incidentally on histological examination, hence there is need for extensive sampling to prevent false negative diagnosis especially in old women. Patient was kept on follow up to prevent further recurrence.

References

1. Kujiper A, Mommers EC, Van der Wall, Van Diest PJ. Histopathology of the fibroadenomas of the breast. *Am J Clin Pathol.*, 2001; 115: 736–42.
2. Abu-Rahmeh Z, Nseir W, Naroditzky I. Invasive ductal carcinoma within fibroadenoma and lung metastases. *Int J Gen Med.*, 2012; 5: 19-21.
3. Shah AK, Pathak R, Banerjee SN, Kaul A, Niazi M, Girishkumar HT. Lobular carcinoma-in-situ within a fibroadenoma of the breast. *Postgrad Med J.*, 1999; 75(883): 293-4.
4. Cheatle GL, Cutler M. Tumours of the breast. Their pathology, symptoms, diagnosis and treatment. London: Edward Arnold & CO; 1931, p. 483-4.
5. Gashi-Luci LH, Limani RA, Kurshumliu FI. Invasive ductal carcinoma within fibroadenoma: A case report. *Cases J.*, 2009; 2: 174.
6. Limite G, Esposito E, Sollazzo V, Ciancia G, Formisano C, Di Micco R, et al. Lobular intraepithelial neoplasia arising within breast fibroadenoma. *BMC Res Notes*, 2013; 6: 267.
7. Ghosh P, Saha K. Ductal carcinoma in situ in a benign phyllodes tumor of breast: A rare presentation. *J Nat Sci Biol Med.*, 2014; 5(2): 470-2.
8. Kuijper A, Preisler-Adams SS, Rahusen FD, Gille JJ, van der Wall E, van Diest PJ. Multiple fibroadenomas harbouring carcinoma in situ in a woman with a family history of breast/ovarian cancer. *J Clin Pathol.*, 2002; 55(10): 795-7.
9. Sarela AI, Madvanur AA, Soonawala ZF, Shah HK, Pandit AA, Samsi AB. Carcinoma in a fibroadenoma. *J Postgrad Med.*, 1995; 41(1): 19-20.
10. Rao S, Latha PS, Ravi A, Thanka J. Ductal carcinoma in a multiple fibroadenoma: Diagnostic inaccuracies. *J Cancer Res Ther.*, 2010; 6(3): 385-7.
11. Ooe A, Takahara S, Sumiyoshi K, Yamamoto H, Shiba E, Kawai J. Preoperative diagnosis of ductal carcinoma in situ arising within a mammary fibroadenoma: A case report. *Jpn J Clin Oncol.*, 2011; 41(7): 918-23.
12. Skaane P, Engedal K. Analysis of sonographic features in the differentiation of fibroadenoma and invasive ductal carcinoma. *AJR Am J Roentgenol.*, 1998; 170(1): 109-14.
13. Azzopardi JG, Ahmed A, Mills RR. Problems in breast pathology. In: Bennigton JC, editors. *Major Problems in Pathology*. Edinburgh: WB Saunders Company Ltd., 1979, p. 325–8.
14. Kwon MJ, Park HR, Seo J, Kim DH, Jung K, Lim YA, et al. Simultaneous Occurrence of Ductal Carcinoma In Situ within Juvenile Fibroadenoma in Both



Breasts: A Brief Case Report. Korean J Pathol., 2014; 48(2): 164-6.

hints on treatment policy. World J Surg Oncol., 2014; 12: 335.

15. Wu YT, Chen ST, Chen CJ, Kuo YL, Tseng LM, Chen DR, et al. Breast cancer arising within fibroadenoma: Collective analysis of case reports in the literature and

Source of support: Nil

Conflict of interest: None declared.