



Case Report

# **Adenoid cystic carcinoma of the parotid gland - A case report and review of literature**

**Nupur Singla<sup>1</sup>, Gunvanti Rathod<sup>2\*</sup>, Disha Singla<sup>3</sup>**

<sup>1</sup>P.G. Student, Radiology Department, SBKS MI & RC, Sumandeep Vidyapeeth, Vadodara, India

<sup>2</sup>Assistant Professor, Pathology Department, SBKS MI & RC, Sumandeep Vidyapeeth, Vadodara, India

<sup>3</sup>P.G. Student, Radiology Department, SBKS MI & RC, Sumandeep Vidyapeeth, Vadodara, India

\*Corresponding author email: [neempath@gmail.com](mailto:neempath@gmail.com)

**How to cite this article:** Nupur Singla, Gunvanti Rathod, Disha Singla. Adenoid cystic carcinoma of the parotid gland - A case report and review of literature. IAIM, 2015; 2(4): 182-186.

**Available online at [www.iaimjournal.com](http://www.iaimjournal.com)**

**Received on:** 08-03-2015

**Accepted on:** 23-03-2015

## **Abstract**

Adenoid cystic carcinoma (ADCC) is a relatively rare malignant salivary gland tumor comprising less than 1% of all malignancies of head and neck. It can arise in any salivary gland site, but approximately 50–60% develops within the minor salivary glands. On fine needle aspiration cytology (FNAC), hyaline globules surrounded by neoplastic cells forming a cell ball are the diagnostic. Adenoid cystic carcinoma, being rare, was not suspected at the first instance. The final diagnosis was made from the cytological, radiological, and histopathological reports.

## **Key words**

Adenoid cystic carcinoma, Malignant salivary gland tumor, Hyaline globules.

## **Introduction**

Adenoid cystic carcinoma (ADCC) is a relatively rare malignant salivary gland tumor comprising less than 1% of all malignancies of head and neck. It is the 5<sup>th</sup> most common malignancy of salivary gland origin, representing 5-10% of all salivary gland neoplasms [1, 2]. It can arise in any salivary gland site, but approximately 50–60% develops within the minor salivary glands. In the parotid gland, the ADCC is relatively rare, constituting only 2–3% of all tumors [3]. Histologically, the tumor consists of three different patterns: cribriform, tubular and solid.

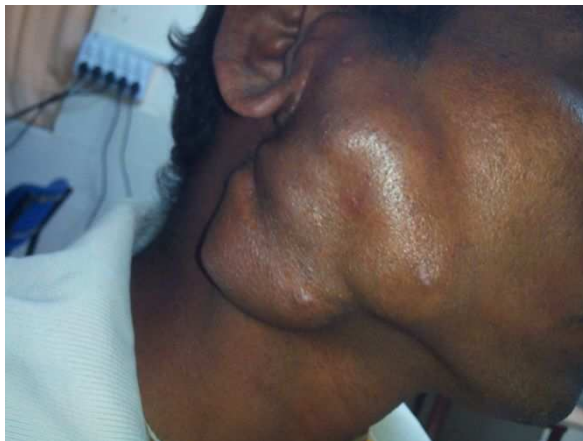Solid pattern is associated with increased local recurrence, high metastatic rate and higher mortality [4]. Here, we have reported a case of adenoid cystic carcinoma of parotid gland in 42 years old male patient with multiple lung metastases.

## **Case report**

A 42 years old, systemically healthy male patient presented with a complaint of pain and swelling on the right side of the face since 5–6 months. The patient reported a rapid increase in size of the lesion over the past 2 months.

On examination, a well-defined swelling on the right side of the face in the parotid region, with an intact surface, measuring approximately 7×6.5 cm in size with no facial nerve palsy was noted. **(Photo – 1)** The lesion was not fixed to the underlying bone and was entirely within the soft tissues. Hematological investigations revealed a normal complete blood count, erythrocyte sedimentation rate, and blood chemistry.

**Photo – 1:** Well-defined swelling on the right side of the face in the parotid region.

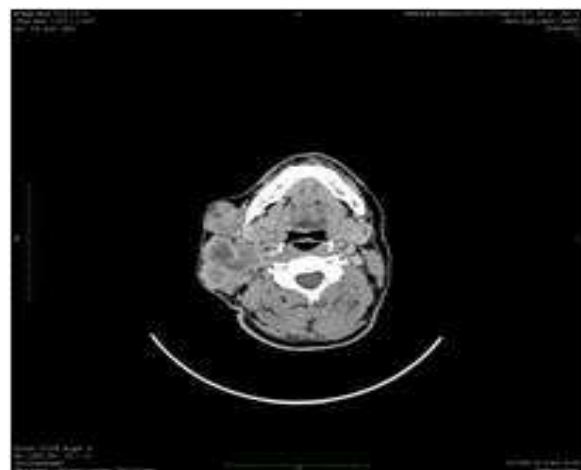

Plain and contrast-enhanced scans with axial and coronal sections revealed a multifocal, mild peripherally enhancing conglomerated lesion of size approximately 74×68 mm in axial plane is seen involving the right parotid gland. **(Photo – 2)** Bilateral lung field showed multiple soft tissue nodular lesion of average size 10×12 mm, suggestive of metastasis. The overall features were suggestive of a mass lesion involving right parotid gland along with preauricular soft tissue nodular lesion. There was presence of multiple lung metastases.

The patient was referred to FNAC clinic. FNAC was performed using a 22-gauge needle attached to a 10 ml syringe [5, 6, 7, 8]. Blood mixed particulate material was obtained, air dried and 95% ethanol fixed smears were made

[9, 10, 11]. Smears were stained with H&E stain (Hematoxylin and Eosin) and Papanicolaou stains. The diagnosis was made on smears stained with H&E stain as these showed the characteristic findings of hyaline globules surrounded by the neoplastic cells forming a cell ball. **(Photo – 3)** These globules stained pale with Papanicolaou stain and were virtually invisible. Individual cell cytology showed cells with small ovoid nuclei, mild to moderate pleomorphism and hyperchromasia and prominent nucleoli. **(Photo – 4)** Cells appeared in small groups, tight clusters and plugs, while some were seen encircling the hyaline globule. Overall features were that of ADCC.

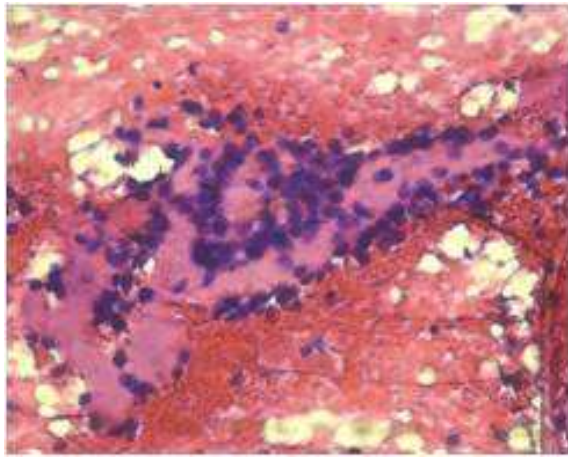
**Photo – 2:** CECT showing large infiltrative soft tissue mass in the parotid region of the right side of the face.



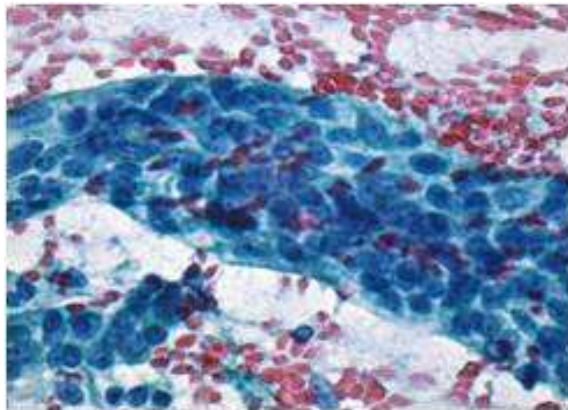
## Discussion

Adenoid cystic carcinoma (ADCC) is a malignant salivary gland tumor that was first described by Billroth in 1859 [12] under the name cylindroma attributing to its cribriform appearance formed by the tumor cells with cylindrical pseudolumina or pseudospaces. The term “adenoid cystic carcinoma” was introduced by Ewing (Foote and Frazell) in 1954. Adenoid cystic carcinoma (ACC) is a slow-growing, but aggressive neoplasm with a remarkable capacity for recurrence.

**Photo – 3:** Hyaline globules surrounded by neoplastic cells forming a cell ball. (H & E Stain, 20X)



**Photo – 4:** Tumor cells having uniform and hyperchromatic nuclei, fine to coarse chromatin pattern with prominent nucleoli. (Pap Stain, 40X)



Clinically, it appears as a slow-growing mass with early local pain, facial nerve paralysis in the case of parotid tumors, fixity to deeper structures and local invasion.

This is an interesting tumor with two distinct clinical entities [13]. One group, as in the present case, has a relentless fulminating course with early metastasis and fatal outcome within a short period of 2-3 years. The second group has an insidious natural history and long survival period despite local recurrences. Most of the cases fall in the second category, “the patient and the tumor existing in symbiosis”. The tumor

grows slowly but infiltrates widely. The mode of spread of this tumor is characteristic. It has a tendency for perineural spread accounting for pain in about 50% of cases. The propensity of this tumor to invade bone and spread along the base of the skull results in extensive intracranial invasion and involvement of the cranial nerves. Lymphatic spread being very rare, lymphadenopathy is seldom encountered. Lymph nodes, however, in very extensive cases, may be involved by direct extension [14]. In long standing cases distant metastasis occurs via the blood stream to the lungs and bones.

Diagnosis of ADCC on FNAC can be made by presence of biphasic cells population: epithelial (usually basaloid) and myoepithelial cells. There is also presence of basement membrane material and hyaline globules which are surrounded by tumor cells. The tumor cells show usually small, uniform and hyper chromatic nuclei, fine to coarse chromatin pattern with prominent nucleoli [15].

The differential diagnosis of ADCC includes polymorphous low grade adenocarcinoma (PLGA), basal cell adenoma (BCA) and mixed tumor (pleomorphic adenoma). PLGA shows uniform cell population with cytologically bland, round or oval vesicular nuclei and pale eosinophilic cytoplasm whereas cells in ADCC have clear cytoplasm, angular, hyper chromatic nuclei and may show mitotic activity. The Ki-67 index is reported to be 10 times higher in ADCC compared to PLGA. Basophilic pools of glycosaminoglycans are seen in ADCC but not in PLGA. Smooth muscle markers of myoepithelial differentiation are positive in ADCC but negative in PLGA [16].

Occasional foci in pleomorphic adenoma (PA) can resemble ADCC but the presence of typical myxochondroid matrix and plasmacytoid or spindle shaped cells helps to avoid confusion



[17]. The three recognized histological variants of ADCC are cribriform, tubular and solid although, cribriform is the most commonest and solid is the least common. Tumor nuclei are typically small, angulated and hyper chromatic with scanty cytoplasm. Mitotic figures are generally scarce in cribriform and tubular areas; however, they are easily visualized in solid standards that have been associated with the worst prognosis [18].

Radiological investigations, especially CT scans are important to delineate the tumor, to plan extent of surgery and to look out for recurrences as a follow up postoperatively. Pulmonary and skeletal surveys are important to rule out distant metastasis. Treatment of these tumors includes surgical excision and postoperative radiation. The role of chemotherapy for metastatic Adenoid cystic carcinoma is still controversial.

### Conclusion

ADCC is a rare malignant tumor of the parotid gland. The primary treatment objective in ADCC patients is local control, normal functionality and distant metastasis prevention. On FNAC characteristic hyaline globules surrounded by neoplastic cells forming a cell ball are the diagnostic. Adenoid cystic carcinoma, being rare, was not suspected at the first instance. The final diagnosis was made from the cytological, radiological, and histopathological reports.

### References

1. Matsuba HM, Spector GJ, Thawley SE, Simpson JR, Mauney M, Pikul FJ. Adenoid cystic salivary gland carcinoma: A histomorphologic review of treatment failure patterns. *Cancer*, 1986; 67: 519–24.
2. Spiro RH, Huvos AG, Strong EW. Adenoid cystic carcinoma: Factors influencing survival. *Am J Clin Pathol.*, 1979; 138: 579–83.
3. Neville, Damm, Allen, Bouquot. *Oral and Maxillofacial Pathology*. 2<sup>nd</sup> edition, p. 426–8.
4. Huang MX, Ma DQ, Sun KH, Yu GY, Guo CB, Gao F. Factors influencing survival rate in adenoid cystic carcinoma of the salivary glands. *Int J Oral Maxillofac Surg.*, 1997; 26: 435–9.
5. Rathod GB, Ghadiya V, Shinde P, Tandan RK. Pleomorphic sarcoma in 60 years old male – A case report. *International Journal of Current Microbiology and Applied Sciences*, 2014; 3(8): 510-517.
6. Gunvanti Rathod, Pragnesh Parmar, Sangita Rathod, Ashish Parikh. Suprascapular malignant fibrous histiocytoma – A case report. *Discovery*, 2014, 12(31): 50-53.
7. Rathod GB, Goyal R, Bhimani RK, Goswami SS. Metaplastic carcinoma of breast in 65 years old female - A case report. *Medical Science*, 2014; 10(39): 77-81.
8. Disha Singla, Gunvanti Rathod. Cytodiagnosis of renal cell carcinoma – A case report. *IAIM*, 2015; 2(2): 133-137.
9. Gunvanti Rathod, Pragnesh Parmar. Fine needle aspiration cytology of swellings of head and neck region. *Indian Journal of Medical Sciences*, 2012; 66: 49-54.
10. Gunvanti Rathod, Sangita Rathod, Pragnesh Parmar, Ashish Parikh. Diagnostic efficacy of fine needle aspiration cytology in cervical lymphadenopathy – A one year study. *International Journal of Medical and Pharmaceutical Sciences*, 2014; 4(5): 1-8.
11. Mobeen Alwani, Gunvanti B. Rathod. Diagnosis of anaplastic thyroid carcinoma on fine needle aspiration



- cytology - A rare case report. IAIM, 2015; 2(3): 183-187.
12. Lucas RB. Pathology of tumors of the oral tissues. 4<sup>th</sup> edition, London: Churchill Livingstone; 1998, p. 330-5.
  13. Eby L. S., Johnson D. S., Baker H. W. Adenoid cystic carcinoma of the head and neck. Cancer, 1972; 29: 1160-1168.
  14. Allen M. S., Marsh W. L. Lymph node involvement by direct extension in advanced Adenoid cystic carcinoma. Cancer, 1976; 38: 2017-2021.
  15. Orell S. R., et al. Manual and Atlas of fine Needle Aspiration Cytology. Churchill Livingstone.
  16. Prasad AR, Savera AT, Gown AM. The myoepithelial immunophenotype in 135 benign and malignant salivary gland tumors other than pleomorphic adenoma. Arch Pathol Lab Med., 1999; 123: 801-6.
  17. Ogawa I, Miyauchi M, Matsuura H. Pleomorphic adenoma with extensive adenoid cystic carcinoma – like cribriform areas of parotid gland. Pathol Int., 2003; 53: 30-4.
  18. Eveson JW, Cawson RA. Tumours of the minor (oropharyngeal) salivary glands: A demographic study of 336 cases. J Oral Pathol., 1985; 14: 500-9.

**Source of support:** Nil

**Conflict of interest:** None declared.