



Case Report

A rare case of right inguinal hemangiopericytoma - Masking the occurrence of right indirect inguinal hernia

Mahim Koshariya^{*}, Vivek Sharma, Arvind Meravi, Krishna Kanwar, Shivang Saxena, S. Shukla, M.C. Songra

Department of Surgery, Gandhi Medical College and Associated Hamidia Hospital, Bhopal, Madhya Pradesh, India

*Corresponding author email: mahimk2000@yahoo.co.uk

How to cite this article: Mahim Koshariya, Vivek Sharma, Arvind Meravi, Krishna Kanwar, Shivang Saxena, S. Shukla, M.C. Songra. A rare case of right inguinal hemangiopericytoma - Masking the occurrence of right indirect inguinal hernia. IAIM, 2015; 2(4): 207-210.

Available online at www.iaimjournal.com

Received on: 08-04-2015

Accepted on: 14-04-2015

Abstract

A hemangiopericytoma is a rare tumor that originates in the pericytes in the wall of capillaries. It is usually benign in nature and is located in the soft tissues. These tumors can originate anywhere in the body where there are capillaries. The most common locations reported are the brain, lower extremities, pelvic area, head, and neck and abdominal cavity. We have reported here a case of hemangiopericytoma in inguinal region in a 70 year old male patient, who presented with right inguinal mass, which was masking the occurrence of right indirect inguinal hernia and diagnosed as hemangiopericytoma by histopathology.

Key words

Hemangiopericytoma, HPC, Surgical excision, Indirect inguinal hernia.

Introduction

Hemangiopericytoma (HPC) was first described by Stout and Murray in 1942. It is a rare type of soft tissue sarcoma with vascular origin arising from the pericytes of Zimmerman in the wall of capillaries [1]. These account for 2-3% of all soft tissue sarcomas, and about 1% of all vascular and CNS tumors [2]. Diagnosis is based on the characteristic histopathological feature which is

a branching stromal vascular pattern with a "staghorn" configuration. These same histologic features may be observed at least focally in 15% of all soft-tissue tumors [3].

It is also called as solitary fibrous tumor (SFT) by Pathologists to describe a heterogeneous group of benign and malignant neoplasm with a morphologic continuum.

These tumors can originate anywhere in the body where there are capillaries. The most common locations reported are the brain, lower extremities, pelvic area, head, and neck. Males and females are equally affected and the median age is 45 years. Patients may exhibit symptoms associated with a local compressive effect on viscera or neurovascular structures. Paraneoplastic syndromes such as hypoglycaemia have also been described [2, 4].

Patients with hemangiopericytoma can present with recurrent tumors, metastatic tumors or both even after 10 years of surgical treatment. The lungs are the most common metastatic site, followed by the bones and the liver [2, 5, 6].

There is no case reported in literature in which inguinal hemangiopericytoma presented with inguinal hernia. Here we present a unique case of a 70 year old male patient, with right inguinal mass, with an underlying indirect inguinal hernia which was an incidental finding at the time of inguinal exploration for the excision of the mass which was later diagnosed as hemangiopericytoma by histopathology.

Case report

A 70 year old patient presented to the surgical outdoor patient department (OPD) with the chief complaint of swelling over right inguinal region for 1 year. The swelling was gradually progressive and grown up to the present size. He also had complaint of occasional pain over right inguinal region during coughing. Patient did not give any past medical or surgical history and there was no positive history of similar illness in the family. On clinical examination, there was a swelling of size approximately 6x6 cm, located at right inguinal region just above and medial to pubic tubercle. It was globular in shape with well defined margins and there was no cough impulse. On palpation, swelling was firm in consistency, immobile and with smooth surface

and regular margins. Reducibility was absent. All routine blood investigations were within normal limit. Ultrasonography of the swelling showed a heterogenous, hypoechoic mass lesion of size 5.6x4.2 cm at clinically palpable site in right inguinal region nodal mass. Magnetic resonance imaging showed a well-defined mass with heterogeneous contrast enhancement. Fine needle aspiration cytology (FNAC) of the swelling revealed occasional cohesive large clusters of oval to spindle cells with oval hyperchromatic nuclei suggestive of hemangiopericytoma.

On surgical exploration of right inguinal region, a highly vascular mass of size 7x6x5 cm found which was located superficially in the soft tissue of inguinal region. We also found an underlying inguinal hernia which was not apparent on preoperative clinical examination. Inguinal mass was locally excised and subsequently hernioplasty was done. Excised specimen (**Figure – 1**) was sent for histopathological examination which showed well encapsulated tumour composed of spindle to ovoid pericytes like cells arranged around blood vessels. No necrosis or increased mitosis was seen, findings were suggestive of hemangiopericytoma. (**Figure – 2, Figure - 3**) Immunohistochemistry report showed cells were diffusely positive for CD 34.

Figure – 1: Gross specimen of hemangiopericytoma.

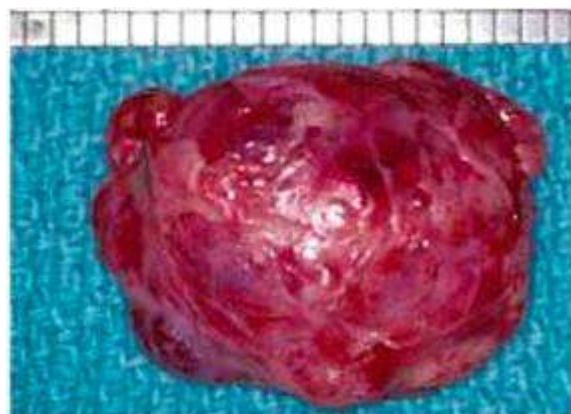
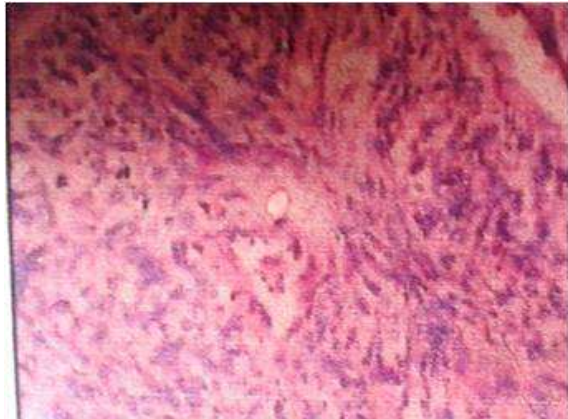


Figure – 2: Histopathology of hemangiopericytoma.



Figure – 3: Histopathology of hemangiopericytoma.



Discussion

Hemangiopericytoma are mostly benign, slow growing tumors located in the soft tissue generally have a good prognosis after curative surgery but the clinical course become complicated by recurrent or metastatic disease which can occur even after 10 to 15 years. Enzinger, et al. had reported 17% metastases and 14% death and a 10-year survival rate of 70% [6]. Espat, et al., reported the relapse rate of 20% at distant site and the overall 5-year survival rate was 86% [2]. As per the previous reports, high local failure rates have been associated with tumors of epidural or retroperitoneal origin, even if wide local resection had been performed however the

local recurrence is not an indicator of poor prognosis [5].

Schirger, et al. [7] had reported on a patient with recurrences up to 26 years after initial curative resection. Morphologic criteria [6, 7, 8, 9] for distinguishing a benign hemangiopericytoma from a malignant tumor are as below.

- Tumor larger than 5 cm in diameter.
- Prominent mitotic activity (more than 4 mitoses per 10 high-power fields).
- Tumor cell necrosis (strong indicator of malignancy).

According to these criteria, the proper diagnosis in the present case would be Hemangiopericytoma with uncertain malignancy.

Curative surgical excision should be done for both primary tumors as well as for locally recurrent masses, and distant metastatic lesions [1, 6] The use of radiotherapy or chemotherapy has no role for the treatment of primary and recurrent tumors, although radiotherapy can be used for metastatic tumors when surgery is no longer feasible [10, 11, 12]. Mostly these tumours are located in the deeper tissue and commonly located sites are lower extremities, pelvic area, head, and neck and abdominal cavity, even it has been reported at thigh and rare sites like pleura. Though no case has been reported of inguinal region and when present at inguinal area over hernia sites one should look for inguinal hernia as it can obscure it diagnosis, which happened in our case.

Conclusion

Hemangiopericytoma is a rare tumor so the surgeon and physician should be reminded to keep in mind when it present as



inguinal swelling. In cases of inguinal mass we should always do FNAC preoperatively because rare tumors like hemangiopericytoma can be one of the differential diagnoses, which can be easily missed. Literature shows it to be a deep seated tumor but rarely it can present in superficial locations like in this case. Do not forget to look for an occult hernia, which can coexist which can be easily missed without proper inguinal exploration. To the best of our knowledge and literature search this is one its own kind of case of hemangiopericytoma inguinal region masking the occurrence of inguinal hernia.

References

1. Stout AP, Murray MR. Hemangiopericytoma: A vascular tumor featuring zimmermann's pericytes. *Ann Surg.*, 1942; 116(1): 26-33.
2. Espat NJ, Lewis JJ, Leung D, Woodruff JM, Antonescu CR, Shia J, et al. Conventional hemangiopericytoma: Modern analysis of outcome. *Cancer*, 2002; 95(8): 1746-51.
3. Gengler C, Guillou L. Solitary fibrous tumour and haemangiopericytoma: Evolution of a concept. *Histopathology*, 2006; 48(1): 63-74.
4. Paullada JJ, Lisci-Garmilla A, Gonzales-Angulo A, et al. Hemangiopericytoma associated with hypoglycemia. Metabolic and electron microscopic studies of a case. *Am J Med.*, 1968; 44(6): 990-9.
5. Spitz FR, Bouvet M, Pisters PWT, Pollock RE, Feig BW. Hemangiopericytoma: A 20-year single institution experience. *Ann Surg Oncol*, 1998; 5: 350-355.
6. Enzinger FM, Smith BH. Hemangiopericytoma. An analysis of 106 cases. *Hum Pathol*, 1976; 7: 61—82.
7. Schirger A, Uihlein A, Parker HL, Kernohan JW. Hemangiopericytoma recurring after 26 years. Report of a case. *Mayo Clin Proc*, 1958; 33: 347—352.
8. Kempson RL, Fletcher CDM, Evans HL, Hendrickson MR, Sibley RK. Tumors of the soft tissues. In *Atlas of tumor pathology, 3rd series*, Armed Forces Institute of Pathology, Washington DC., 1998; p. 371—377.
9. Yagil Barazani, Basir Tareen. Rare case of paratesticular solitary fibrous tumour (lipomatous hemangiopericytoma). *Can Urol Assoc J.*, 2012; 6(3): E131-E133.
10. Beadle GF, Hillcoat BL. Treatment of advanced malignant hemangiopericytoma with combination Adriamycin and DTIC: A report of four cases. *J Surg Oncol*, 1983; 22: 167—170.
11. Celik I, Bascil N, Yalcin S, et al. Ifosfamide-based chemotherapy for recurrent or metastatic hemangiopericytoma. *Acta Oncol*, 1997; 36: 348.
12. Staples JJ, Robinson RA, Wen B-C, Hussey DH. Hemangiopericytoma - The role of radiotherapy. *Int J Radiat Oncol Biol Phys*, 1990; 19: 445—451.

Source of support: Nil

Conflict of interest: None declared.