

Original Research Article

Magnetic resonance imaging in focal liver lesions: Imaging with pathological correlation


R. Archana^{1*}, A. Suman Chandra², M. Vijaya Kumari³, Yamini⁴

¹Assistant Professor, ²Professor and HOD, Department of Radiology, Osmania General Hospital, Hyderabad, India

³Professor, Department of Radiology, Niloufer Hospital, Hyderabad, India

⁴Consultant Radiologist, India

*Corresponding author email: adiiti1234@yahoo.com

| | | |
|--|--|--------------------------------------|
|  | International Archives of Integrated Medicine, Vol. 3, Issue 11, November, 2016. Copy right © 2016, IAIM, All Rights Reserved. Available online at http://iaimjournal.com/ | |
| | ISSN: 2394-0026 (P) | ISSN: 2394-0034 (O) |
| | Received on: 12-10-2016 | Accepted on: 20-10-2016 |
| | Source of support: Nil | Conflict of interest: None declared. |
| How to cite this article: R. Archana, A. Suman Chandra, M. Vijaya Kumari, Yamini. Magnetic resonance imaging in focal liver lesions: Imaging with pathological correlation. IAIM, 2016; 3(10): 1-9. | | |

Abstract

Background: Magnetic resonance signal intensity of focal liver lesions is affected by numerous pathologic factors. Lesion histologic features, such as cellularity, vascularity, stromal component, and intratumoral necrosis or hemorrhage, strongly affect T1 and T2 relaxation times.

Aim: Our study is done to assess the lesion characterization potential of MRI by evaluating unenhanced and dynamic gadolinium enhanced sequences.

Materials and methods: A total of 50 consecutive patients who were diagnosed by sonography as having focal liver lesions for period of 2 years were included in the study.

Results: Most of the patients are of 30 - 60 years. The mean age for malignant lesions is 51 years. Of 50 patients 32 are males and 18 are females. Male: female ratio 2:1. 65% of the lesions are located in right lobe of the liver. The most common benign lesion encountered was liver abscess followed by haemangiomas and most common malignant lesion was metastases. Abscess and hemangiomas were predominant in benign whereas metastases and hepatocellular carcinomas were predominant in malignant lesions. The difference in mean ADC values in both the groups was significant.

Conclusions: MR imaging is a powerful tool for the evaluation of focal liver lesions. Pre contrast T1 weighted gradient echo images, T2 weighted images, inphase and out phase imaging, EPI - DWI and gadolinium enhanced T1 weighted images provide accurate characterization of the lesions.

Key words

Magnetic resonance imaging, Sonography, Focal liver lesions.

Introduction

Magnetic resonance signal intensity of focal liver lesions is affected by numerous pathologic factors. Lesion histologic features, such as cellularity, vascularity, stromal component, and intratumoral necrosis or hemorrhage, strongly affect T1 and T2 relaxation times. Additionally, intracellular content of certain substances, such as glycogen, fat, melanin, iron, and copper, may also have a substantial role in determining MR signal behavior. The exact prevalence of benign liver masses is unknown but some studies suggest that they may be found in more than 20% of the general population [1]. Recent studies suggest that small (<15 mm) lesions that are detected on CT are benign in more than 80% of the patients who have known malignancy. With the application of multi-row detector CT and thin collimation, it is likely that more liver lesions will be detected that will need additional imaging for characterization, most likely with MR imaging.

In patients with cirrhosis, early diagnosis of malignant changes is of vital importance as liver transplantation offers the best chance for survival. Recognizing dysplastic and regenerative nodules and early hepatocellular carcinoma helps to control tumour burden at early stages by nonsurgical techniques while awaiting transplantation as well as stratifies the patients who have favourable long term results with transplantation. It is also important to distinguish benign and malignant liver lesions. Several malignancies, such as breast, pancreas and colorectal tumours metastasize to liver. The survival rate following the resection of isolated metastasis especially in colorectal malignancies can be as high as 38% [2].

MRI is particularly well-suited to the evaluation of liver pathology due to an ability to generate contrast by a variety of mechanisms. This allows specific evaluation of important diffuse processes

such as abnormal fat, as may be seen in non-alcoholic sceaotohepatitis, or iron accumulation as seen in hemochromatosis. The use of intravenous gadolinium-based contrast agents allows evaluation of the vascular supply to benign and malignant tumors, yielding important diagnostic information. Use of contrast-enhanced IT for multiphase examinations is associated with an ionizing radiation burden that is proportional to the number of scans obtained during the study. There are increasing concerns regarding the risks of radiation and the iodinated contrast agents associated with CT imaging of the abdomen. MRI can be very useful for confirming the diagnosis of hemangioma, focal nodular hyperplasia, complex cyst, etc. without the need for biopsy, surgery, or multiple follow-up examinations.

The longer scan times, motion artifacts associated with the conventional spin echo sequences are now overcome by the gradient echo, fast spin echo and fat saturation techniques. Intravenous gadolinium contrast agents provide additional opportunities for the characterization of the lesions. Diffusion weighted imaging enables qualitative and quantitative assessment of tissue diffusivity (apparent diffusion coefficient) without the use of gadolinium chelates, which makes it a highly attractive technique, particularly in patients with severe renal dysfunction at risk for nephrogenic systemic fibrosis [3].

Our study is done to assess the lesion characterization potential of MRI by evaluating unenhanced and dynamic gadolinium enhanced sequences.

Materials and methods

A total of 50 consecutive patients who were referred to the department of Radiodiagnosis, Osmania General Hospital and were diagnosed by sonography as having focal liver lesions from

December 2012 and August 2014 were included in the study after informed consent.

In all studies MR imaging was performed with a clinical 1.5 T system (General electrical medical systems). A dedicated phased-array body coil was used.

Sequences

- Axial T2-weighted FSE with TR/TE 1826/180, Field of view 40x40cm, Matrix 256 x 256, Slice thickness 5mm with interslice gap of 2.5mm, number of excitations (NEX) = 0.5
- Axial pre contrast LAVA with TR = 4.4, TE = 2, slice = 5 mm with interslice gap of 2.5mm, average MA = 320 x 160, NEX = 0.7
- Axial in phase and opposed phase 2D SPGR sequences were acquired.
- Dynamic Gd-enhanced MR imaging using the fat-suppressed Multiphase LAVA was subsequently performed in the arterial, portal venous phases and equilibrium phases. The imaging parameters were kept identical.

Diffusion-weighted respiratory-triggered single-shot spin echo echoplanar imaging (SS SE-EPI) sequence using b-values 600 s mm^{-2}

A power-injector was used for the gadolinium injections (Omniscan, GE health care, 0.1 mmol/kg body weight; injection rate 2 ml/s). Liver-specific contrast agent agents were not included in our clinical routine.

The quantitative analysis of the diffusion (ADC) was calculated on a workstation by applying a ROI on the image

Image Analysis

On the basis of signal characteristics, enhancement patterns, morphology and diffusion and adc maps the lesions are characterized. The sizes and numbers of liver lesions as well as the hepatic segments involved were recorded for the

solid lesions. Couinaud's anatomical description of eight liver segments for lesion localization was used. Coexisting benign lesions such as hemangiomas and cysts were also noted. The anatomical proximities of the lesions to the inferior vena cava or hepatic veins, hepatic hilum, and to the main portal branches were assessed. For this purpose, a scale for the lesion's proximity of less than 1 cm or more than 1 cm was used. Benign or suspected malignant lymph nodes were scrutinized and the possibility of other extrahepatic involvement such as infiltration through the hepatic capsule or peritoneal metastases was considered.

Histopathology

Tissue diagnosis (Fine needle aspiration cytology/ trucut biopsy) is obtained in feasible cases. In case of patients with hemangiomas and simple cysts either follow up (average 7.6 months) or post surgical histopathology has been considered.

Results

A total of 50 consecutive patients who were diagnosed by sonography as having focal liver lesions for period of 2 years were included in the study. MRI features with focal liver lesions were studied and morphological features and signal intensities of the masses were described.

Most of the patients are of 30 - 60 years. The mean age for malignant lesions is 51 years. Of 50 patients 32 are males and 18 are females as per **Table - 1**. Male: female ratio 2:1 (approximately). Right side of liver lobe is more affected in study as per **Figure - 1**.

Abscess was more in benign lesions (**Table - 2**), metastasis was common in malignant. Characterization of the lesions was as per **Figure - 2**. Enhancement patterns on gadolinium enhanced MRI was as per **Table - 3**.

Discussion

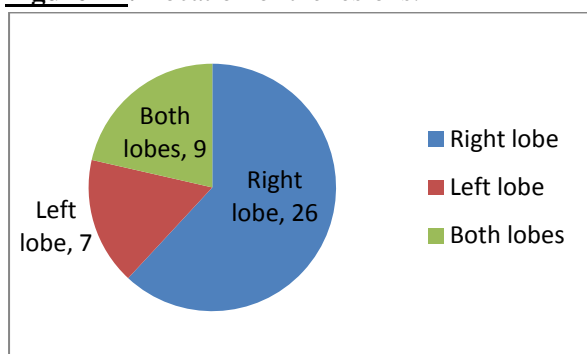
The study was done on 50 patients of which contrast was given in 46 members. Focal liver

lesions were analyzed based on clinical findings, laboratory investigations and MR imaging. Sonographically detected focal lesions were included in the study. Tissue diagnosis (FNAC/ Biopsy), surgery were done in feasible cases.

Table - 1: Demographic distribution.

| Age | No. of Patients | % |
|---------------|-----------------|----|
| 10-20 years | 1 | 2 |
| 20 - 30 years | 6 | 12 |
| 30 - 40 years | 16 | 32 |
| 40 - 50 years | 5 | 10 |
| 50- 60 years | 20 | 40 |
| 60 - 70 years | 2 | 4 |
| >70years | 0 | 0 |
| Sex | | |
| Male | 32 | 64 |
| Female | 18 | 36 |

Figure - 1: Location of the lesions.



MR Imaging

Our study group consisted of 50 patients. We considered multiple lesions of similar morphology in a single patient as a single lesion. Metastasis are the most common malignant lesion and abscesses are the most common benign lesions. The size of the lesions varied from 0.7cm to 14 cm with an average of 6.3 cm for malignant lesions and 5.5cm for benign lesions. The size of the lesions is not predictive of the malignant character of the lesion.

Lesion detection

Of the total Lesions detected by contrast enhanced sequences, 90% were detected on T2

WI and 97% were detected on diffusion weighted images. Diffusion weighted images were able to detect small metastatic lesions which were inconspicuous on T2 weighted images. These small lesions were also identified on gadolinium enhanced scans. According to Parikh et al⁴ the malignant focal liver lesions detected by DW imaging (86.4%) was significantly greater than that detected with T2-weighted imaging [62.9%]. But this statistical significance is lost with increasing size of the lesions. In our study the average size of the malignant lesions was 6.3cm. Hence the detection rates of the lesions were higher as well as the significance of DW imaging is decreased. In a study by funda obuz, et al. [5] overall MR imaging sensitivity for detection of small lesions (<1 cm) was 13- 67%, while for large lesions (>3 cm) it was 100%.

Table - 2: Incidence of benign and malignant lesions.

| Lesions | Nature of the lesions | |
|---------------------------|-----------------------|-----------|
| | Benign | Malignant |
| Simple cysts | 4 | - |
| Abscess | 10 | - |
| Hydatid cysts | 6 | - |
| Haemangiomas | 4 | - |
| Focal fat sparing | 0 | - |
| Biliary cystadenoma | 2 | - |
| Focal nodular hyperplasia | 1 | - |
| Metastasis | - | 12 |
| Hepatocellular carcinoma | - | 3 |
| Cholangiocarcinoma | - | 3 |
| Pseudolesions | 1 | - |
| Total | 28 | 22 |

When assessed for image quality, the T2 weighted images have the best quality and less number of artifacts. The cystic lesions were more conspicuous on T2 weighted images whereas metastases were conspicuous on DW imaging. This is in accordance with other studies which highlights SE-EPI DWI as a promising technique for detecting small (<10 mm) focal malignant

liver lesions. The reason for a high detection rate of focal hepatic lesions on DWI is attributed to the better contrast-to-noise ratio and better lesion conspicuity by suppression of background vessels. Furthermore, the solid tumours tended to appear larger on DWI than on T2 weighted images. This phenomenon may contribute to the high detection rate of small solid tumours on DWI. Although the use of T2 weighted images is helpful for the detection of the focal hepatic lesions lesion detectability is suppressed by low lesion-to-liver contrast and the interfering high signal intensity from intrahepatic vessels, Intrahepatic vessels may be seen as false positive lesions on T2 weighted images small benign solid tumour might not be detected on T2 weighted images because of less conspicuity of the solid lesions by the magnetisation transfer effect. However in our study when compared with contrast enhanced sequences DW imaging detected lower number of lesions (90%). Combined use of DW imaging and contrast enhanced scans provide highest sensitivity for lesion detection [6].

Lesion characterization

The results show that the classification into malignant and benign liver lesions and the assessment of specific diagnosis were most reliably achieved when all sequences were collectively evaluated. Several previous investigations also advocate the use of a combination of sequences in liver diagnostics. Coulam, et al. [7] reported a sensitivity of 97% and a specificity of 95% in revealing clinically relevant focal liver lesions using a T1- weighted multiphase contrast-enhanced 3D sequence. Similar results are encountered in the present study.

According to the present results, the best individual sequence in distinguishing between malignant and benign liver lesions is the dynamic Gd-enhanced T1-weighted sequence. This sequence also demonstrated the highest success in the assessment of specific diagnosis, with a 90% rate of correct diagnosis. Several previous studies support this result as Gd-enhancement,

particularly when used in a dynamic fashion in different phases of enhancement, has been considered to be highly important in liver tumor characterization.

T2 weighted images are limited in characterization of malignant liver lesions as they have varied appearances. They are more important in imaging of hemangiomas. Reduced lesion conspicuity and the overlap in signal intensity characteristic of benign and malignant nodules diminished the diagnostic value of T2-weighted images in cases of cirrhotic liver, too. Farland, et al. [8] found that Hemangiomas and malignant tumors are better differentiated with use of T2 relaxation times obtained with a more heavily T2-weighted sequence.(T2 : 140 s). In our study out of 4 hemangiomas T2 WI was able to characterize three of them. All the three hemangiomas had high signal intensity on T2 WI and heavily weighted T2 sequences. But as some of the hyper vascular metastasis can have longer T2 relaxation times, contrast examination was done in all these cases. One patient with carcinoid metastasis had the metastatic lesion with longer T2 relaxation times. The fourth patient with hemangioma had a large lesion and had varied appearance on T2 WI. Contrast enhancement was diagnostic in that patient. Overall T2 WI has a detection rate of 92% in our study.

Benign lesions were seen in 28 patients. Of these there were two simple cysts. These cysts were detected incidentally in one patient with pancreatitis and other with bladder malignancy. These cystic lesions showed well defined thin wall with intense hypointense signal on T1 WI and intense hyper intense signal on T2 WI which increased on heavy T2 sequences. These lesions showed no enhancement on contrast administration. These lesions were followed up with sonography which showed no increase in size and number of the lesions. One patient had polycystic liver disease with multiple well defined cystic lesions without any communication with biliary system. All the cysts were intensely hypointense on T1 WI without any evidence of hemorrhage. One patient had

segmental Carolis disease with multiple cystic lesions which represent dilated non obstructed biliary radicals. Multiple intra hepatic calculi are found within them. All the cystic lesions were is to moderately hyper intense on DWI.

There were ten cases of abscess. Seven of the cases were pyogenic abscesses and 3 of them were Amoebic liver abscess. The lesions were hypointense on T1 WI and hyperintense on T2 WI. Perilesional edema is seen around four of lesions (57%). This is not specific for abscesses as it is also seen with malignancies, but is useful for characterization as mentioned by Mendez, et al. [9]. One patient in acute stage showed cluster of high signal intensity lesions. This grouped appearance is suggestive of pyogenic abscess.

To differentiate simple cysts, abscess and hydatid cysts with diffusion weighted imaging, the ADC value has been calculated. The mean ADC value of simple cysts and hydatid cysts (2.4×10^{-3}) was significantly higher than the mean ADC value of the abscesses (1.2×10^{-3}) in our study. These results were in accordance with the studies by Nagihan, et al. [10].

Biliary cystadenoma, seen in a two patient, is multiseptated lesions with hypointense signal on T1WI and hyperintensity on T2 WI. On contrast administration there is enhancement of the capsule and internal septations. Differentiation from hydatid cyst is difficult, but enhancement of the internal septae with no evidence of daughter cysts and with vascularity noted within the internal septations on colour Doppler is diagnostic.

Focal nodular hyperplasia is another benign entity seen in a young female with idiopathic pulmonary and portal hypertension. There is evidence of large homogenous lesion which is hypointense on T1WI and isointense on T2WI with a central scar that is hyperintense on T2 WI. On contrast administration there is intense homogenous enhancement on arterial phase with delayed enhancement of the scar. Two small additional lesions were identified on contrast

administration which were missed on T1 and T2 WI due to the isointensity of the lesions. Multiplicity of the FNH can be seen in 20% of the cases (Nguyen BN, et al., 1999). In a study by Vilgrain, et al. [11], of 37 patients with pathologically proven focal nodular hyperplasia, only eight patients (22%) had multiple lesions. For the association between FNH and pulmonary hypertension, it has been suggested that chronic congestion of the hepatic sinusoids can prolong the exposure of the liver to blood-borne hepatotropic substances that induce a hyperplastic response of the hepatic parenchyma, and this stimulates the growth of nodular hepatocellular lesions such as FNH, which is a compensatory vicious cycle. Portman, et al. [12] described a case of nodular transformation of liver in case of non cirrhotic portal hypertension and pulmonary hypertension. Ultrasound guided Fine needle aspiration biopsy showed dense fibrous septum with vascular structures and adjacent hepatic parenchyma showed increased cell plate thickening. The dense cellularity is responsible for the hypointense signal intensity on T2 WI and the vascularity for the intense arterial phase enhancement.

Of the 50 cases imaged, 22 patients harboured malignant lesions. Hepatocellular carcinoma was seen in 6 cases. 4 cases showed solitary lesions whereas multiple nodules were noted in two cases. All the cases were hypointense on T1 WI and hyperintense on T2 WI. Three of the lesions showed central hyperintensity which corresponded with necrotic areas on pathology. These areas were non enhancing on contrast administration. Hypointense areas on T2 WI were noted in two of the cases which corresponded with fibrotic areas. Tumour capsule was noted in four of the cases (80%). This is a characteristic sign of large HCCs. The capsule is seen normally in 60-82% of the cases. In one study, 56 of the 72 HCCs showed a capsule at histology and 75% of the lesions with a capsule were larger than 2 cm. The tumour capsule becomes thicker with increasing tumour size. It is hypointense on T1 and T2 weighted images. Contrast enhancement was either homogenous or variegated arterial phase

enhancement. The variegated appearance noted is due to abnormal internal vessels in the lesion. In one study by Matilde, et al. [13], in a total of 31 patients with hepatocellular carcinoma, 13 lesions showed homogenous enhancement, 9 lesions showed variegated appearance and 7 lesions showed ring enhancement and two of them showed no enhancement (42)t. In our study 4 patients showed homogenous enhancement and one patients showed variegated appearance. The lesion which showed mosaic pattern on T2 weighted images showed heterogenous enhancement on gadolinium- enhanced images. The mosaic pattern on T2 weighted images is due to the histopathology of the tumour. Tumour which showed variegated appearance had confluent nodules that are separated by thin septae and necrotic areas within the tumour on histopatology. This reflects the characteristic growth pattern of HCC. Portal vein encasement is seen in one case. Portal vein involvement is seen more often in infiltrative type of HCCs.

Of the 9 metastases, two were from pancreatic adenocarcinoma, one metastases was from gallbladder malignancy, two are from gastric neoplasms (one GIST and one gastric carcinoma), one is adenocarcinomatous deposit from unknown origin, one metastases is from carcinoid bowel, two are from colon malignancy. The metastases from bowel are having typical target like appearance on T2 weighted images. All the metastases were having intermediate to high signal intensity on T2 weighted images. These lesions are not as bright as cysts and hemangiomas. On contrast administration 8 of these 9 lesions showed ring enhancement with complete pattern. One metastases showed incomplete ring pattern. Perilesional enhancement is seen with one case with metastases from pancreatic adenocarcinoma. All the lesions were bright on diffusion weighted imaging with an average ADC value: 1.34×10^{-3} . In one study by Matilde, et al. [13], out of 47 patients with metastases, 40 lesions showed ring like enhancement, one lesion showed incomplete ring, and 7 lesions showed no enhancement. Of the 4 cases with intrahepatic

cholangiocarcinoma, hypointense area is noted on T2 weighted images in two of the cases corresponding with central fibrosis. There is peripheral intrahepatic ductal dilatation in all the four cases. Intrahepatic dilatation is also noted with one hepataocellular carcinoma. Subcapsular atrophy is noted in two cases. On gadolinium administration contrast enhancement is noted in delayed phases (3-5minutes delayed phase). This is related to the abundant fibrous stroma of the cholangiocarcinoma. This is specific for intrahepatic cholangiocarcinomas. Maetani Y, et al. [14] in a study in 50 patients correlated the imaging findings and pathological features of cholangiocarcinoma and concluded that the occurrence of a central hypointense area on T2-weighted images is not pathognomonic; however, this finding, which reflects severe fibrosis, appears to be a characteristic marker of intrahepatic cholangiocarcinoma. The presence of intrahepatic bile duct dilatation may indicate cholangiocarcinoma, although it is difficult to differentiate cholangiocarcinoma from hepatic colorectal metastasis, which might also show biliary dilatation.

The mean ADC value of benign lesions (cysts, haemangiomas and benign nodular lesions) was $2.092 \times 10^{-3} \text{ sec/mm}^2$ and that of malignant lesions was $1.241 \times 10^{-3} \text{ sec/mm}^2$. The difference in mean ADC values in both the groups was significant ($p < 0.0001$). The threshold ADC values to distinguish the above two groups was determined to be $1.43 \times 10^{-3} \text{ sec/mm}^2$ by ROC analysis. ADC values $< 1.43 \times 10^{-3} \text{ sec/mm}^2$ gave a sensitivity of 100% and specificity of 86% for detecting malignant lesions. The causes for false negatives were focal benign solid lesions and early abscesses and false positives were necrotic metastases.

Out of 7 hepatocellular carcinomas, correct diagnosis was made in four cases. One case of multifocal HCC, in view of intense arterial enhancement and multiple lesions of varying sizes, hypervascular metastases was considered. One lesion thought to be metastases, in patient with adenocarcinoma in head of pancreas

showing ring enhancement and intermediate signal intensity on T2 weighted images, turned out to be early abscess. The ADC value of the lesion is 1.2×10^{-3} . Fine needle aspiration and cytology revealed neutrophils and debris. Follow up studies showed it to be an abscess. Another patient having multiple small ring enhancing lesions in right lobe of liver with target appearance on T2 weighted images and perilesional T2 hyperintensity and perilesional enhancement was thought to have cystic metastases. Aspirate showed pus within the lesions and follow up studies showed response with antibiotic therapy.

One patient had Budd chiari syndrome with multiple nodules which are hypointense on T1 WI and of intermediate signal intensity on T2 WI, showing delayed enhancement on T2 WI. These nodules were indeterminate on MRI as benign regenerative nodules almost never show increased signal intensity on T2 weighted imaging and hepatocellular carcinoma/ dysplastic nodules show intense arterial enhancement. Tissue diagnosis showed that these nodules are benign regenerative nodules. Review of literature showed that benign nodules in Budd chiari syndrome can show increased T2 signal intensity⁶. Central area altered signal intensity which is hypointense on T1 weighted images and hyperintense on T2 weighted images is noted in many nodules in the patient. This corresponded with central scarring. In a study by Maetani, et al. [14] of 15 lesions larger than 1 cm in diameter, a central scar was found with either CT or MR imaging in six nodules. In the delayed phase of contrast-enhanced imaging, the central scar showed high signal intensity. They concluded that central scar is a characteristic finding of benign hepatic nodules larger than 1 cm in Budd-Chiari syndrome.

Thus MRI was able to predict histological diagnosis in 45 of the 50 focal liver lesions, accounting for 90% of the tumors.

Conclusions

MRI was able to predict diagnosis in 45 of the 50 tumours. It could suggest the nature of all lesions in benign cysts, hemangiomas, focal nodular hyperplasia and metastases. But it was not possible to achieve a specific diagnosis in two early abscess, one multifocal hepatocellular carcinoma and one case of regenerative nodules. This accounted for a detection rate of 90%. Thus MR imaging is a powerful tool for the evaluation of focal liver lesions. Pre contrast T1 weighted gradient echo images, T2 weighted images, in phase and out phase imaging, EPI - DWI and gadolinium enhanced T1 weighted images provide accurate characterization of the lesions. The varied appearances of the lesions on these sequences are the result of the dominant histological composition of the lesions.

References

1. Francis I R, Cohan R H, Me Nulty N J, Platt J F, et al. Multidetector CT of the Liver and Hepatic Neoplasms: Effect of Multiphasic Imaging on Tumor Conspicuity and Vascular Enhancement. *AJR*, 2003; 180: 1217-24.
2. Haider MA, Amitai MM, Rappaport DC, et al. Multi-detector row helical CT in preoperative assessment of small (<1.5 cm) liver metastases: Is thinner collimation better? *Radiology*, 2002; 225(1): 137-42.
3. Vaills C, Andia E, Sanchez A, et al. Hepatic metastases from colorectal cancer: preoperative detection and assessment of resectability with helical CT. *Radiology*, 2001; 218: 55-60.
4. Parikh T, Drew SJ, Lee VS, Wong S, Hecht EM, Babb JS, et al. Focal liver lesion detection and characterization with diffusion-weighted MR imaging: comparison with standard breath-hold T2-weighted imaging. *Radiology*, 2008; 246: 812-22.
5. Obuz F, Oksüzler M, Seçil M, Sağol O, Karademir S, Astarcioglu H. Efficiency of MR imaging in the detection of

- malignant liver lesions. *Diagn Interv Radiol.*, 2006; 12(1): 17-21.
6. Pawluk RS, Tummala S, Brown JJ, Borrello JA. A retrospective analysis of the accuracy of T2 - weighted images and dynamic gadolinium-enhanced sequences in the detection and characterization of focal hepatic lesions. *J Magn Reson Imaging.*, 1999; 9: 266-73.
 7. Coulam CH, Chan FP, Li KC. Can a multiphasic contrast-enhanced three-dimensional fast spoiled gradient-recalled echo sequence be sufficient for liver MR imaging? *AJR Am J Roentgenol.*, 2002; 178: 335-41.
 8. McFarland EG, Mayo-Smith WW, Saini S, Hahn PF, Goldberg MA, Lee MJ. Hepatic hemangiomas and malignant tumors: improved differentiation with heavily T2-weighted conventional spin-echo MR imaging. *Radiology*, 1994; 193(1): 43-7.
 9. Méndez RJ, Schiebler ML, Outwater EK, Kressel HY. Hepatic abscesses: MR imaging findings. *Radiology*, 1994; 190(2): 431-6.
 10. Inan N, Arslan A, Akansel G, Anik Y, Sarisoy HT, Ciftci E, Demirci A. Diffusion-weighted imaging in the differential diagnosis of simple and hydatid cysts of the liver. *AJR Am J Roentgenol.*, 2007; 189(5): 1031-6.
 11. Vilgrain V, Fléjou JF, Arrivé L, Belghiti J, Najmark D, Menu Y, et al. Focal nodular hyperplasia of the liver: MR imaging and pathologic correlation in 37 patients. *Radiology*, 1992; 184(3): 699-703.
 12. Portmann B, Stewart S, Higenbottam TW, Clayton PT, Lloyd JK, Williams R. Nodular transformation of the liver associated with portal and pulmonary arterial hypertension. *Gastroenterology*, 1993; 104(2): 616-21.
 13. MatildeNino-Murcia M, Olcott EW, Jeffrey RB Jr, Lamm RL, Beaulieu CF, Jain KA. Focal liver lesions: pattern based classification scheme for enhancement at arterial phase CT. *Radiology*, 2000; 215(3): 746-51.
 14. Maetani Y, Itoh K, Egawa H, Haga H, Sakurai T, Nishida N, Ametani F, Shibata T, Kubo T, Tanaka K, Konishi J. Benign hepatic nodules in Budd-Chiari syndrome: radiologic-pathologic correlation with emphasis on the central scar. *AJR Am J Roentgenol.*, 2002; 178(4): 869-75.