


Original Research Article

# Role of mast cells and neuronal hypertrophy in acute appendicitis

K. Bhrmaramba<sup>1\*</sup>, Shyamala Srujana<sup>2</sup>, P. Rama Devi<sup>3</sup>, O. Shravan Kumar<sup>4</sup>

<sup>1</sup>Associate Professor, <sup>2</sup>Assistant Professor, <sup>3</sup>Post Graduate, <sup>4</sup>Professor and HOD  
Department of Pathology, Gandhi Medical College, Hyderabad, India

\*Corresponding author email: [bkaryampudi@gmail.com](mailto:bkaryampudi@gmail.com)

	International Archives of Integrated Medicine, Vol. 3, Issue 11, November, 2016. Copy right © 2016, IAIM, All Rights Reserved. Available online at <a href="http://iaimjournal.com/">http://iaimjournal.com/</a> ISSN: 2394-0026 (P) ISSN: 2394-0034 (O)	
	Received on: 23-08-2016 Source of support: Nil	Accepted on: 21-09-2016 Conflict of interest: None declared.
<b>How to cite this article:</b> K. Bhrmaramba, Shyamala Srujana, P. Rama Devi, O. Shravan Kumar. Role of mast cells and neuronal hypertrophy in acute appendicitis. IAIM, 2016; 3(11): 94-102.		

## Abstract

Acute appendicitis is a common surgical emergency. Appendix continues to be the major chunk of surgical specimens received in Pathology laboratory. However, pathogenesis of appendicitis remains poorly understood. Obstruction and inflammation is implied in pathogenesis of acute appendicitis. Presently there is increasing evidence of involvement of enteric nervous system in immune regulation and in inflammatory responses. The present study combines routine histopathology and immunohistochemistry to study the role of mast cells and enteric nervous system in pathophysiology of acute appendicitis. We have done a prospective study for a period of one and half years from January 2014 to July 2015. Appendectomy specimens from patients who are clinically diagnosed as acute appendicitis were included in study group as cases. Appendix specimens removed at Forensic autopsies were used as controls. Study was conducted on total 138 appendix specimens of which 118 were surgically removed from patients with acute appendicitis, taken as study group. 20 specimens from Forensic autopsy, were used as comparison group (normal control group). We found a consistent increase in mast cell and neuronal counts along with prominence of ganglion cells in specimens with acute appendicitis compared to the control group.

## Key words

Appendicitis, Appendectomy, Neuronal hypertrophy, Ganglion cells, Mast cells.

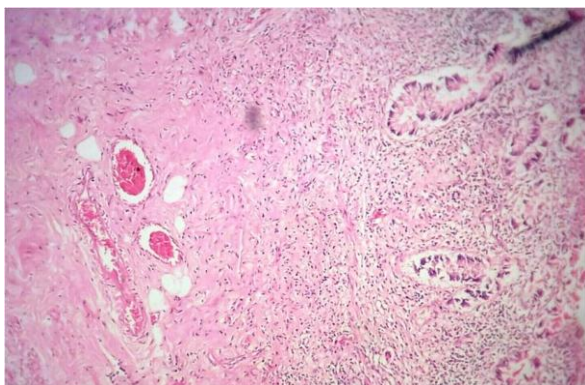
## Introduction

Appendectomy is the most frequent intra abdominal surgery and it is the most common

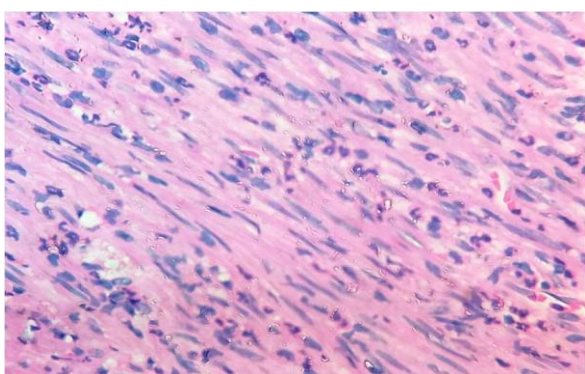
surgical emergency in children [1]. 6% to 20% of the general population develop appendicitis during their lifetime and about 1 in every 6

people undergoing appendectomy [2]. 20% to 30% appendices removed from patients with suspected appendicitis appear normal on histology [3]. The cause of acute abdominal pain in these patients remains unexplained. In most of these patients appendectomy proves curative [4]. Obstruction and inflammation is implicated in the pathogenesis of acute appendicitis (**Figure – 1, 2**). Fecolith and lymphoid hyperplasia is seen in only small percentage of cases. This discrepancy between clinical presentation and the lack of definite morphologic changes is confounding.

**Figure - 1:** H & E, (BxNo.2/15) 40X: Histology of normal appendix from control.



**Figure - 2:** H & E, (BxNo.530/15)40X: HPAA- Presence of neutrophils in muscularis propria.



Recent studies revealed there is increasing evidence of involvement of the enteric nervous system in immune regulation [5]. It is suggested from the close spatial and functional relationship that exists between nerves and immunocompetent cells like mast cells. It is also

suggested by presence of receptors for neuropeptides on immunocompetent cells throughout the gastrointestinal tract. Increased proliferation of nerves, as well as increased levels of neurotransmitters such as substance P and vasoactive intestinal peptide, have been reported. Mast cells have a central role in type I hypersensitivity leading to recruitment of eosinophils and discharge of primary and secondary mediators of inflammation. Mast cells have been implicated in pathogenesis of pain and are frequently opposed to peripheral nerves [6-9]. On stimulation, these cells release mediators, which cause clinical symptoms of nausea, vomiting and abdominal pain in patients who were clinically diagnosed as acute appendicitis but had apparently normal histology.

### **Aim and objectives**

- To study the various pathological changes in surgically removed appendices with the clinical diagnosis of acute appendicitis, but no evidence of acute appendicitis, histologically.
- To study role of mast cells, eosinophils, neuronal hypertrophy and ganglion cells, in normal and inflamed appendices.
- To compare mast cell counts in various layers of appendix in different histopathological groups and to characterize status of enteric nervous system in normal and in inflamed appendices.

### **Materials and methods**

The present study was conducted in Department of Pathology, Gandhi Medical College/ Hospital. The study was conducted for a period of one and half year from January 2014 to June 2015. A descriptive study was conducted on 138 appendix specimens of which 118 were surgically resected and 20 were obtained at forensic autopsy. 118 appendices from patients who were clinically diagnosed as acute appendicitis were taken as study group (cases) and 20 appendices from forensic autopsy were taken as comparison group (normal control)

appendices). 20 cases of histologically negative, 20 cases of histologically positive and 10 controls were randomly selected for immunohistochemistry. Gangrenous and perforated appendices were not included in the study. The patient's age and sex was recorded.

Appendices were fixed in 10% formalin. After fixation one section each taken from tip, base and intermediate length, and routine processing was done. 3 paraffin sections of 5 micron thickness were cut from each block. One of the sections was stained by Haematoxylin & Eosin for various findings of appendicitis, one for 1% Toluidine blue staining for identification of mast cells and 3<sup>rd</sup> section for IHC by S- 100.

### **Quantitative analysis of immune stained sections for number and size of ganglia**

To give a quantitative estimation of number & size of ganglia, the greatest dimensions of ganglia were measured and the number of ganglion cells/hpf were counted, using 'OCULAR MICROMETER [10]. The calibration of ocular micrometer was done using a STAGE MICROMETER total length of 1mm, composed of 100 equal divisions with a least count of 0.01 mm. That yields a least count of 9.8µm per division of ocular micrometer under magnification of 10X (low power) and 2.5µm per division under 40X (high power).

The number of divisions of ocular micrometer spanned by each ganglion in greatest dimension is evaluated and result expressed in micrometers. The dimensions so obtained of all the ganglia in each of 10 high power fields per specimen are noted.

## **Results**

In the present study among 118 patients, 65 were females accounting up to 55% and 53 were males accounting up to 45%, with female to male ratio 1.2:1. Most of the patients in study group were presented with sudden onset of pain in the lower abdomen followed by vomiting and fever. Gross examination of specimens revealed varied length,

average measuring 7.5cm in length. External surface congested in all the specimens and cut section showed patent lumen in some, fecolith in some.

The 118 appendices (study group) were divided into two categories on microscopy;

- Group "A"- HNAA: Histologically negative acute appendicitis (69 cases- 58.4%).
- Group "B" – HPAA: Histologically positive acute appendicitis (49 cases- 41.5%).
- 20 appendices from forensic autopsy were considered as Group 'C' (controls).

The mast cells were counted in 10 contiguous fields (in all layers) using 40X objective lens and 10× eye piece. The average number of mast cells per hpf was calculated and expressed as [11];

- 0-2/ hpf (Grade 1+),
- 2.1 -4/hpf (Grade 2+),
- 4.1-6/hpf (Grade 3+)
- More than 6/hpf (Grade 4+).

Of these 138 (cases + controls) appendices, mucosal mast cells <4/hpf was seen in 122 cases and >4/hpf in 16 cases. In submucosa, mast cells <4/hpf were seen in 89 cases and >4/hpf in 49 cases. In muscularis mast cells <4/hpf were seen in 118 cases and >4/hpf in 20 cases. There were no cases with mast cells >4 / hpf in the serosa. In submucosa and muscularis propria mast cell counts in group 'A' (HNAA) and group 'B' (HPAA) were higher than those in group 'C' (Controls). Mast cells were highest in submucosa in all Groups. In submucosa, mast cells were larger, ranging from spindle to polygonal in shape and they contained coarse and numerous granules.

### **Quantitative estimation of size and number of ganglia**

Greatest dimensions of ganglia in 10 high power fields were measured by calibrated ocular micrometer for the number of divisions it spans and the value is multiplied by conversion factor

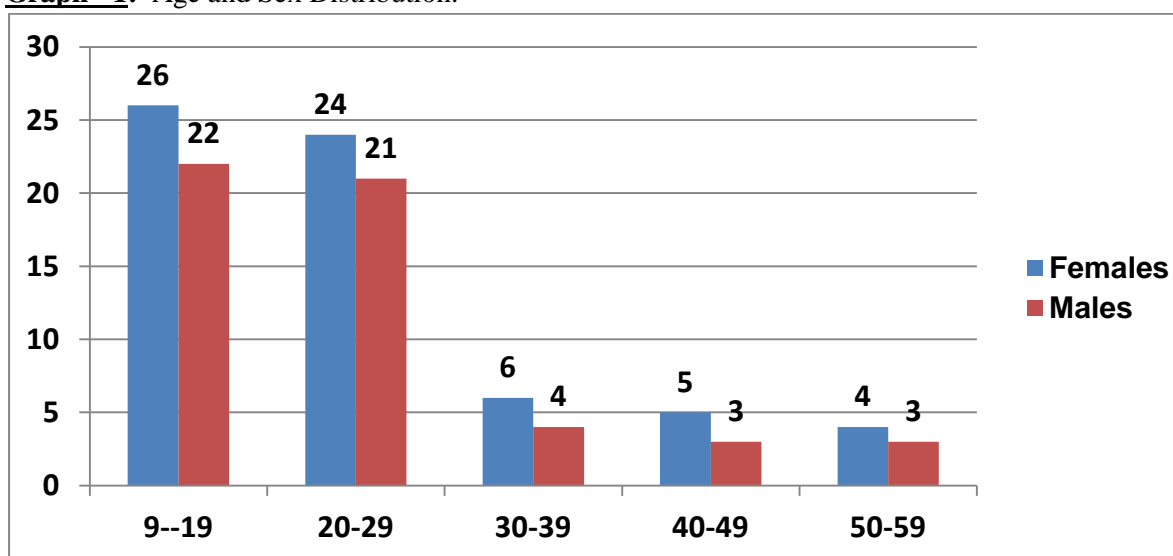
(for 10X; 1 division = 9.8µm; 40X; 1 division= 2.5µm). Ganglion cells were counted in 10 high power fields per specimen.

## Discussion

Highest incidence of appendicectomy was seen in females (**Graph - 1**) in our study similar to observation seen by Lee [12]. In our study maximum number of cases were seen between age group of first and second decades of life (**Table - 1**), similar to Ashwini kolar, et al. Mast

cells were in highest concentration in submucosa (**Figure - 3, 4, 5**) in all the categories (**Table - 2**), similar to U.R. Singh study [13] (**Table - 3**). Xiong, et al. [5] and coskun, et al. [14] evaluated mast cell density, neuronal hypertrophy in patients with acute appendicitis using Image analysis software (SAMBA 2005: Alkatel - TITN, France). According to their study protocol, Mast cells were stained with tryptase and evaluated by analysis soft ware.

**Graph - 1:** Age and Sex Distribution.



**Table - 1:** Age and sex distribution.

Age	Females	Males	Total
09-19	26	22	48
20-29	24	21	45
30-39	06	04	10
40-49	05	03	08
50-59	04	03	07
<b>Total</b>	<b>65</b>	<b>53</b>	<b>118</b>

Mast cells (MCs) are derived from the bone marrow and are frequently located at body sites that interface with the external environment, such as the skin, respiratory tract and gastrointestinal mucosa. They serve a function of host defence against invading pathogens and have a central role in the mediation of allergic responses [15, 16]. Although Mast cells synthesise a wide variety of mediators that can induce both acute

and chronic inflammation [17], they also generate and release several mediators that may act on nerve development and neural functions, and contribute to neuroimmune reactions [18, 19]. They synthesise, store and release several mediators that may influence neural functions such as leukaemia-inhibitory factor, IL-6 and TNF. Mast cells exert their biological effects by releasing preformed mediators stored in granules

such as leukotrienes, prostaglandins, and cytokines [20]. There is considerable evidence that mast cells are micro anatomically and functionally opposed to the peripheral nerves [21], resulting in a homeostatic unit in the regulation of gut physiology and host defence.

**Table - 2:** Distribution of cases according to presence of mast cells in all the four layers of appendices.

MC/hpf	Mucosa			Submucosa			Muscularis propria			Serosa		
	HNAA	HPAA	C	HNAA	HPAA	C	HNAA	HPAA	C	HNAA	HPAA	C
0-2	49	29	18	06	16	10	33	35	18	45	42	17
2.1-04	07	17	02	30	18	09	19	11	02	24	07	03
4.1-6	11	03	00	19	03	01		02	00	00	00	00
>6	02	00	00	04	22	00	06	01	00	00	00	00
<b>Total</b>	69	49	20	69	49	20	69	49	20	69	49	20

(C=Controls)

**Table - 3:** Comparative study of mast cells (Mean mast cell count).

Groups	Present Study	U.R. Singh, et al. Study [13]
<b>SUB MUCOSA</b>		
HNAA	18.05	22.20
HPAA	16.03	18.05
Controls	4.01	7.04
<b>MUSCULARIS PROPRIA</b>		
HNAA	7.02	8.80
HPAA	6.04	10.08
Controls	2.03	4.06

**Table - 4:** Number and Size of Ganglia in Different Groups.

GROUPS	MEAN SIZE OF GANGLIA (greatest dimension – in muscularis propria)	MEDIAN GANGLION CELL COUNT / 10hpf
‘A’ - HNAA	198.82±71µm	50
‘B’ -HPAA	166.44±56µm	44.5
‘C’ -CONTROLS	70.08±28µm	21.5

The increase in mast cells in acute appendicitis (HNAA, HPAA) together with the broad spectrum of activities of mast cell-derived mediators, suggests that this cell type could play a role in the pathogenesis of acute appendicitis. Recent studies have also demonstrated the involvement of the enteric nervous system (ENS) and Mast cells during intestinal inflammation [22]. Ganglia were found between the circular and longitudinal layers and also deep within the muscle layers. Only mild neural hyperplasia was

seen in all cases of acute appendicitis on H & E staining and may be explained by the mucosal destruction and dense inflammatory exudates that obscure the morphology of the tiny nerve twigs. Immuno-staining by S-100 is mandatory in such cases to make an accurate estimation like in the present study and was in agreement with that of Xiong, et al. [5]. He found an increased number and enlarged ganglia and increased number of mast cells in the submucosa and muscularis externa in all cases of acute appendicitis and in

40% of apparently normal appendices having symptoms of appendicitis (**Table - 5**), as compared to controls. Xiong, et al. [5] and Coskun, et al. [12] evaluated mast cell density, neuronal hypertrophy and nerve growth factor in patients with acute appendicitis using Image analysis software( SAMBA 2005: Alkatel-TITN, France). According to their study protocol;

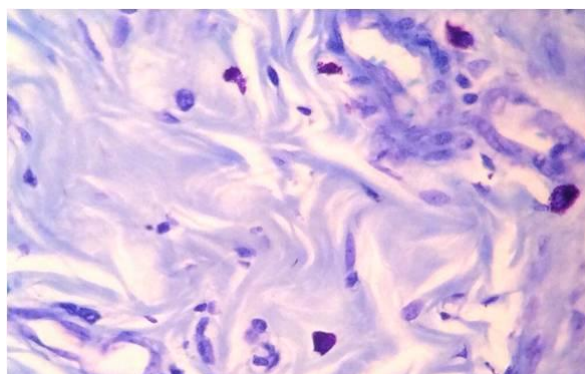
Staining was done for ganglia by S-100 in Xiong, et al. [5] study and by PGP 9.5 IHC marker in Coskun, et al. [12] study. Density of ganglia and mean area of ganglia were estimated with SAMBA software. The results showing increased number and size of ganglia in acute appendicitis, compared to controls (**Table - 5**).

**Table - 5:** Comparison of Ganglia.

Xiong, et al. [5] Study			Present Study		
Area of ganglia/ $\mu\text{m}^2$	Acute appendicitis	672.6 $\pm$ 47.8	Mean size of ganglia (greatest dimension-muscularis propria)	HNAA	198.82 $\pm$ 71 $\mu\text{m}$
	Controls	269.0 $\pm$ 25.9		HPAA	166.44 $\pm$ 56 $\mu\text{m}$
Number of ganglia/ $\text{mm}^2$	Acute appendicitis	3.9 $\pm$ 0.9	Median ganglion cell count/10hpf	Controls	70.08 $\pm$ 28 $\mu\text{m}$
				HNAA	50
	HPAA	44.5			
	Controls	1.6 $\pm$ 0.7		Controls	21.5

In the present study, Staining was done by S-100 IHC marker, Mean size of ganglia in its greatest dimension ( $\mu\text{m}$ ) was evaluated using calibrated ocular micrometer (**Figure - 6**). Density of ganglia was expressed as median number of ganglion/10hpf (**Table - 4**). We also found the number and size of ganglia in muscularis propria were higher (**Table - 4, Figures - 7, 8, 9**) in group 'A' (HNAA) and group 'B' (HPAA) when compared to group 'C' (Controls).

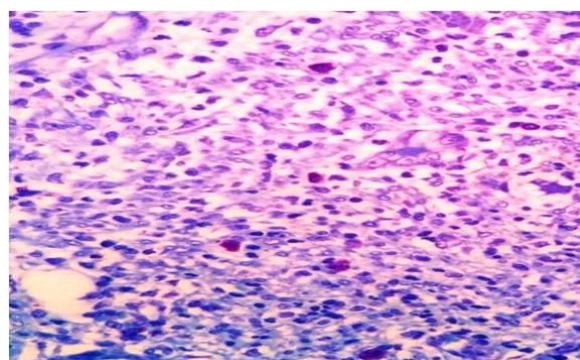
**Figure - 3:** Toluidine blue, (BxNo.184/15) 40x: Grade III mast cells in HNAA.



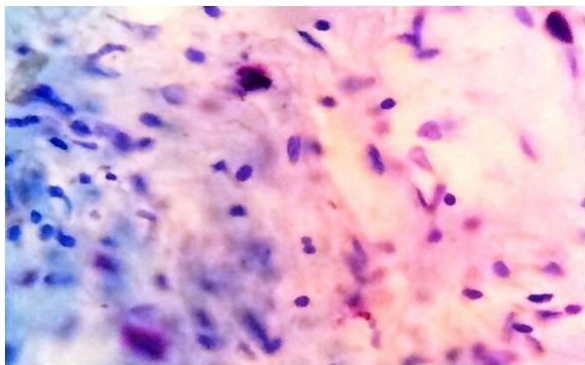
Neural components seen in muscular layer of appendices in HNAA cases were increased or comparable with cases of HPAA (**Figures - 10, 11, 12**) suggesting the possibility of right iliac

fossa pain in the absence of inflammation. Peripheral nerves may physiologically be in a constant state of remodelling under different situations and that a variety of stimuli, such as inflammation or injury, can effect or affect nerve remodeling. Neural proliferation may therefore represent a form of inflammatory response. Well-developed neuronal changes of the extent seen in this study are unlikely to develop during a single episode of acute inflammation (frequently bouts of only hours or days in duration) and suggest a pre-existing stimulus such as repeated episodes of subclinical inflammation or a response to an obstruction.

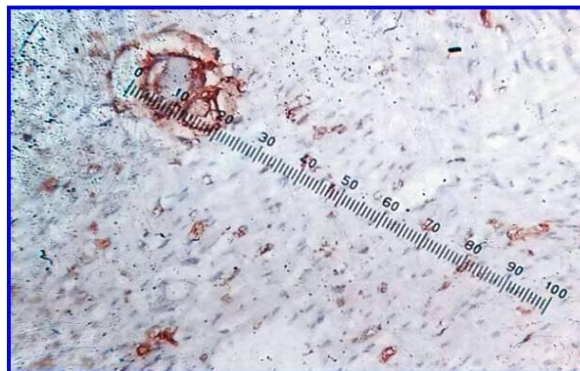
**Figure - 4:** Toluidine blue, (BxNo.288/15) 40x: Grade III mast cells in HPAA.




**Figure - 5:** Toluidine blue, (BxNo.4/15) 40x: Grade II mast cells in normal appendix.



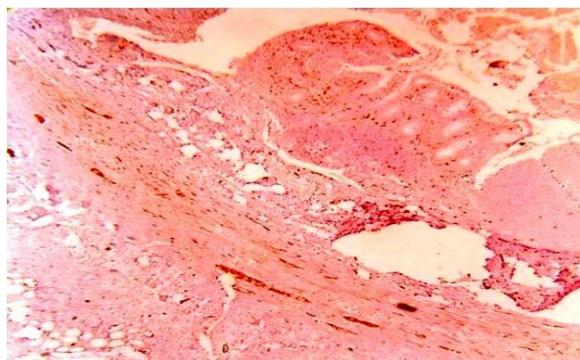
**Figure - 9:** IHC with S 100, (BxNo.5/15) 40x: Normal ganglia from control specimen.



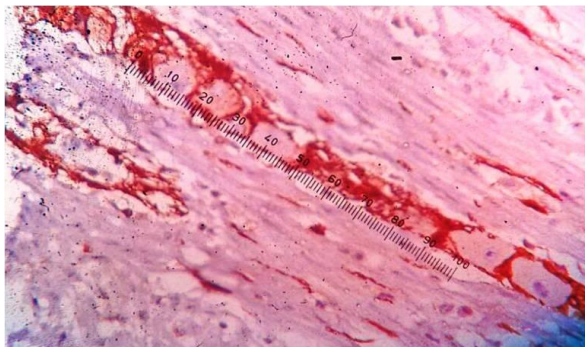
**Figure - 6:** Calibration of OCULAR MICROMETER, Top column is ocular micrometer, Bottom column is stage micrometer.



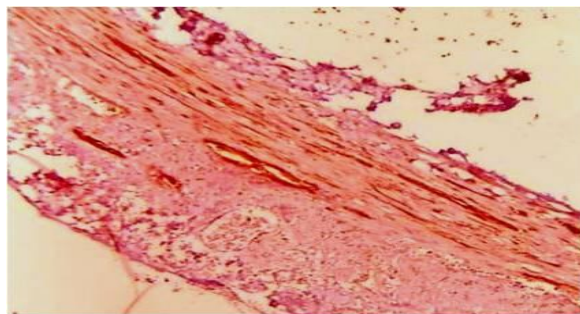
**Figure - 10:** IHC with S100, 10X: increased number of nerve fibers, in HNAA.



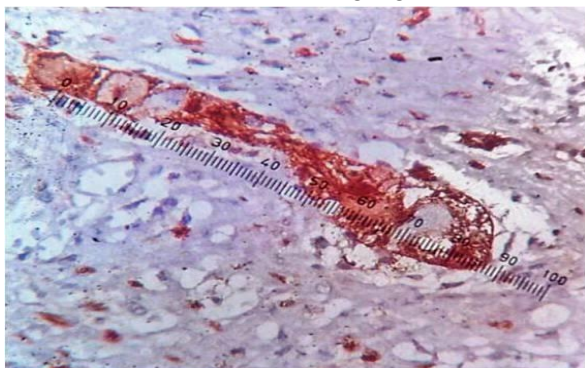
**Figure - 7:** IHC with S-100, (BxNo.12/15) 40X: Increased number and size of ganglia in HNAA.



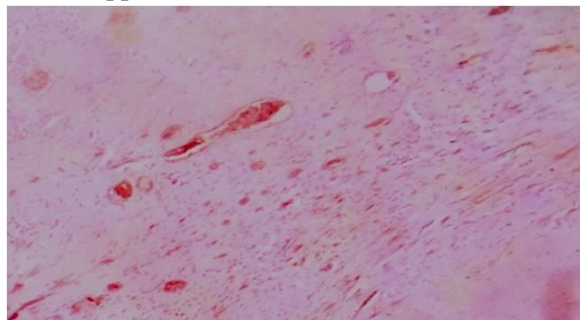
**Figure - 11:** IHC with S100, 40X: increased number of nerve fibers, in HPAA.



**Figure - 8:** IHC with S-100, (BxNo.24/15) 40x: Increased number and size of ganglia in HPAA.



**Figure - 12:** IHC with S100, (BxNo.8/15) 40X: normal appendix.



Recently, an increase in neural components and neuropeptides observed in clinically suspected but histopathologically normal appendices [23]. It has been proposed that the neuronal cell hypertrophy might represent the reparative phase of an inflammatory process to previous chronic or repeated acute injury. It is more appropriate to suggest that acute appendicitis might represent an exacerbation of an inflammatory process that already exists in the appendix. Mast cells have been demonstrated to possess receptors for NGF and interestingly are a newly recognized source of NGF synthesis, storage and release [24]. In inflammatory bowel disease, an increase in NGF expression was found in inflamed tissues and infiltrating Mast cells also expressed enhanced levels of NGF. It has been suggested that NGF and Mast cells contribute to nerve activation and remodeling during inflammation.

Our results thus suggest that increased mast cells and neural components reflect the interaction of Mast cells and ENS during inflammation of the appendix rather than a physiological aging phenomenon.

## Conclusion

The increased number of mast cells and ganglion cells in acute appendicitis indicate that the inflammation is neurogenic in nature. As neuronal hypertrophy is a chronic process, its consistent presence in specimens of clinically positive acute appendicitis would suggest that it is an acute manifestation of a chronic process. The increase in S100-immunopositive neuronal components in a substantial proportion of so called negative appendectomies further supports this hypothesis. The increase in mast cell counts, nerves along with prominence of ganglion cells in acute appendicitis establishes functional link between the enteric nervous system, mast cells, and the pathogenesis of acute appendicitis.

## References

1. Lee Frederick D, Anderson NH, Toner PG. Non-neoplastic diseases of the small

and large intestine. In: Silverbergh S, Delellis R, Frable WJ, editors. Principles and practice of surgical pathology and cytopathology, 3<sup>rd</sup> edition. Churchill Livingstone, Edinburgh: Publishers; 1997.p.1789–92.

2. Jess P, Bjerregaard B, Brynitz S, Holst-Christensen J, Kalaja E, Lund-Kristensen J. Acute appendicitis. Prospective trial concerning diagnostic accuracy and complication. *Am J Surg.*, 1981; 141(2): 232-34.
3. Jones MW, Paterson AG. The correlation between gross appearance of the appendix at appendectomy and histological examination. *Ann R Coll Surg Engl.*, 1988; 70: 93–4.
4. Miettinen P, Pasanen P, Lahtinen J, Kosonen P, Alhava E. The long-term outcome after negative appendix operation. *Am Chir Gynaecol.*, 1995; 84: 267–70.
5. Xiong S, Puri P, Nemeth L, Reen DJ. Neuronal hypertrophy in acute appendicitis. *Arch Pathol Lab Med.*, 2000; 124: 1429–33.
6. Freemont AJ, Jeziorska M, Hoyland JA, Rooney P, Kumar S. Mast cells in the pathogenesis of chronic back pain: a hypothesis. *J Pathol.*, 2002; 197: 281–85.
7. Barbara G, Stanghellini V, De Giorgio R, Corinaldesi R. Functional gastrointestinal disorders and mast cells: implication for therapy. *Neurogastroenterol Motil.*, 2006; 18(1): 6–17.
8. Hoogerwerf W A, Gondesens K, Xiao SY, Winston JH, Wills WD, Pasricha PJ. The role of mast cells in the pathogenesis of pain in chronic pancreatitis. *BMC Gastroenterol.*, 2005; 5: 8.
9. Anaf V, Chapron C, El Nakadi I, De Moor V, Simonart T, Noel JC. Pain, mast cells and nerves in peritoneal, ovarian and deep infiltrating endometriosis. *Fertil Steril.*, 2006; 86(5): 1336–40.



10. James W. Smith, Yezid Gutierrez. Calibration of Ocular Micrometer. In: Todd, Sanford, Davidson, editors. *Clinical Diagnosis and Management by Laboratory Methods*, 7<sup>th</sup> edition. W.B.Saunders Publishers; 1989, p. 1211.
11. S. Amber, A.M. Mathai, R. Naik, M.R. Pai, S .Kumar, K. Prasad. Neuronal hypertrophy and mast cells in histologically negative, clinically diagnosed acute appendicitis: a quantitative immunophenotypical analysis. *Indian J Gastroenterol.*, 2010; 29(2): 69-73.
12. LEE JA. The influence of sex and age on appendicitis in children and young adults. *Gut*, 1962; 3: 80-84.
13. Singh UR, Malhotra A, Bhatia A. Eosinophils, mast cells, nerves and ganglion cells in appendicitis. *Indian J Surg.*, 2008; 70(5): 231-34.
14. Coşkun N, Indel SM, Elpek GO. Mast cell density and neuronal hypertrophy in patients with acute appendicitis. *Turk J Gastroenterol.*, 2003; 14: 54–8.
15. Bochner BS, Lichtenstein LM. Anaphylaxis. *N Engl J Med.*, 1991; 324: 1785–90.
16. Galli SJ. New concepts about the mast cell. *N Engl J Med.*, 1993; 328: 257–65.
17. Gordon JR, Burd PR, Galli SJ. Mast cells as a source of multifunctional cytokines. *Immunol Today*, 1990; 11: 458–64.
18. Nakafuku M, Satoh T, Kaziro Y. Differentiation factors including nerve growth factor, fibroblast growth factor and interleukin-6 induce and accumulation of an active Ras-GTP complex in pheochromocytoma PC12 cells. *J Biol Chem.*, 1992; 263: 19448–454.
19. Selmaj KW, Raine CS. Tumor necrosis factor mediates myelin and oligodendrocyte damage in vitro. *Ann Neurol.*, 1988; 23: 339–46.
20. Galli SJ, Gordon JR, Wershil BK. Mast cell cytokines in allergy and inflammation. *Agents Actions*, 1993; 43: 209–20.
21. Dvorak AM, McLeod RS, Onderdonk AB, et al. Human gut mucosal mast cells ultrastructural observations and anatomic variation in mast cell nerve association in vivo. *Int Arch Allergy Immunol.*, 1992; 98: 158-68.
22. Baird AW, Cuthbert AW. Neuronal involvement in type 1 hypersensitivity reactions in gut epithelia. *Br J Pharmacol.*, 1987; 92: 647–55.
23. Di Sebastiano PL, Fink T, Weihe E, et al. Changes of protein gene product 9.5 (PGP 9.5) immunoreactive nerve in inflamed appendix. *Dig Dis Sci.*, 1995; 40: 366-72.
24. Tam SY, Tsai M, Yamaguchi M, Yano K, Butterfield JH, Galli SJ. Expression of functional TrkA receptor tyrosine kinase in the HMC-1 human mast cell line and in human mast cells. *Blood*, 1997; 90: 1807–820.