


Original Research Article

Role of MRI in post traumatic posterior urethral distraction defects in comparison to RGU/ MCUG

G Sudarshan*, B Santhosh, S Srinivas, K Seshu Mohan, D Aman Chandra

Department of Urology, Osmania General Hospital, Hyderabad, India

*Corresponding author email: gskn2008@gmail.com

	International Archives of Integrated Medicine, Vol. 3, Issue 12, December, 2016. Copy right © 2016, IAIM, All Rights Reserved. Available online at http://iaimjournal.com/	
	ISSN: 2394-0026 (P)	ISSN: 2394-0034 (O)
	Received on: 28-09-2016	Accepted on: 06-10-2016
	Source of support: Nil	Conflict of interest: None declared.
How to cite this article: G Sudarshan, B Santhosh, S Srinivas, K Seshu Mohan, D Aman Chandra. Role of MRI in post traumatic posterior urethral distraction defects in comparison to RGU/ MCUG. IAIM, 2016; 3(12): 99-107.		

Abstract

Pelvic fracture urethral injuries are typically partial and more often complete disruptions of the most proximal bulbar and distal membranous urethra. Emergency management includes suprapubic tube placement. Subsequent primary realignment to place a urethral catheter remains a controversial topic, but what is not controversial is that when there is the development of a stricture (which is usually oblitative with a distraction defect) after suprapubic tube placement or urethral catheter removal, the standard of care is delayed urethral reconstruction with excision and primary anastomosis. This paper reviews the management of patients who suffer pelvic fracture urethral injuries and the techniques of preoperative urethral imaging and subsequent posterior urethroplasty.

Key words

MRI, RGU, MCUG, Traumatic posterior urethral distraction defects.

Introduction

Pelvic fracture trauma in males, often secondary to motor vehicle trauma or pelvic crush injuries, can be associated with injuries to the posterior urethra, especially where there is pubic symphysis diastasis or there are displaced inferomedial pubic bone fractures. The term

“prostatomembranous disruption” is often used to describe these injuries, and this terminology suggests that the transection occurs at the junction of the prostatic and membranous portions of the posterior urethra. However, more recent studies, including an autopsy review of male patients who sustained pelvic fracture

related urethral injuries and died of associated multiple trauma, revealed that the injuries are generally membranous and distal to the urogenital diaphragm. There can be proximal or distal extension, but the injury generally remains distal to the verumontanum of the prostate.

The classic sign of urethral injury in a patient with a pelvic fracture is blood at the urethral meatus, but other symptoms such as bladder distension, inability to void, and perineal hematoma should raise a high index of suspicion as well.

The treatment options for post traumatic, prostatic membranous urethral distraction defect include, and progressive perineal anastomotic urethroplasty and transpubic urethroplasty. Selection of the appropriate procedure is essential for a successful result, and the appropriate procedure can be anticipated by using certain preoperative information. A number of variables appear to be important, such as the stricture length, the extent of the periurethral fibrosis, presence of true urethral stricture versus distraction defect, and the normality of the anterior urethra.

The preoperative evaluation includes- rectal examination with combined RGU/ MCUG to determine the length of the urethral defect. Unfortunately, this evaluation provides limited information on the actual length of the urethral defect, the position of the prostate, and the extent of the fibrosis. The length of membranous urethral stricture is difficult to determine due to 'poor filling of the prostatic urethra with contrast material.

Magnetic resonance (MR) imaging has been found to be accurate in demonstrating the stricture length and displacement of the prostate apex. Sagittal views determine the prostatic dislocation in anteroposterior and superoinferior direction, while the coronal images determine the right to left dislocation. T2 weighted images can differentiate between soft tissue edema, fibrosis and hematoma. The soft tissue details by MRI

determine the avulsion of the corpus cavernosa which can indicate these patients will develop permanent impotence. The purpose of our study to evaluate the role of MR urethrography in the management of posterior urethral distraction defects.

Materials and methods

Patients from December 2005 through February 2008, 19 men (mean age 24 years; range, 16-42 years) with posttraumatic posterior urethral stricture underwent MR imaging before planned definitive surgery. 19 of these patients were evaluated by using conventional RGU combined with VCUG prior to MR imaging. All patients had a urethral injury due to pelvic trauma. The interval between the original trauma and the MR imaging, varied from 3 to 8 months (mean, 4.7 months). The institutional review board at our medical center approved the study, and informed consent was obtained from all patients.

Imaging Examinations

RGU combined with VCUG

Three hundred milliliters to 500 mL of iodinated contrast material was 'instilled into the bladder through the suprapubic cystostomy catheter to the patient's tolerance. During fluoroscopic observation, the patient was asked to void and then approximately 20 mL of diluted contrast was infused simultaneously into the urethra with a syringe and a urethral catheter. Images were obtained with the patient in the oblique position during maximum urethral distention (**Photo – 1 to 6**).

MR imaging

MR imaging examinations is performed with 1.5 T signa unit with transaxial T1- weighted imaging (repetition time msec=500, echo time msec=20), The T2 weighted imaging in transaxial, sagittal, and coronal imaging done.

The MR Imaging is performed after RGU combined with VCUG examinations, and the time between performance of MR imaging and RGU combined with VCUG imaging ranged

from 4 to 10 days. Before MR imaging, the penis was positioned anteriorly in the supine position' and taped to the abdominal wall beneath the surface coil. MR images were obtained by using a 1.5-Tesla MR imaging device. The MR imaging protocol consisted of a sagittal T2-weighted fast spin-echo sequence and a transverse T2-weighted fast spin-echo sequence.

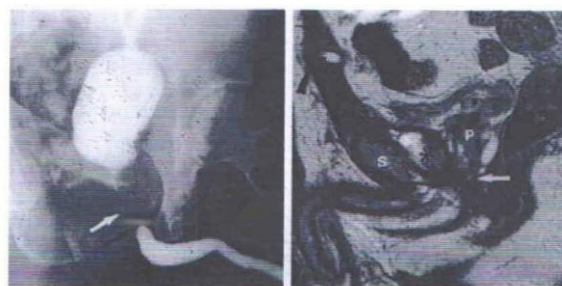
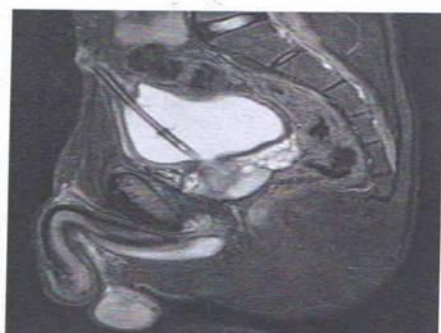
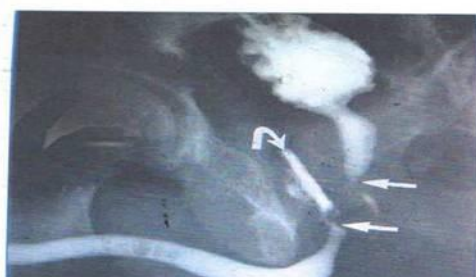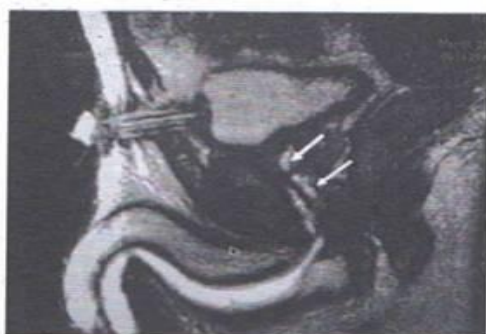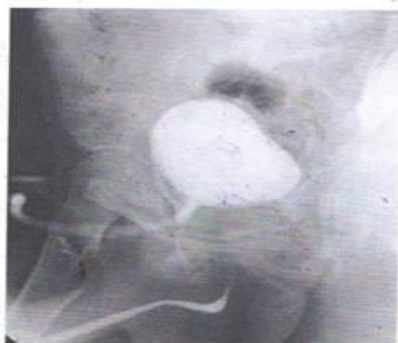Photo – 1 to 6: MR imaging.



Immediately after completion of the MR imaging examination and while the patient was on the table of the MR imager, 150-300 mL of normal saline was injected slowly into the emptied bladder through the suprapubic cystostomy catheter until -the_ patient felt the need to void. The sterile lubricating jelly with 10 ml syringe was instilled into the anterior urethra until resistance was felt and some of the lubricating jelly overflowed from the urethral meatus.

Image Analysis

We have evaluated MRI along with the conventional RGU combined with VCUG images. The following MR imaging findings were evaluated (a) length of membranous urethral injury, as measured by the distance between the prostatic apex and the bulb of the penis on sagittal MR images (b) displacement of the prostate gland in superior inferior, antero posterior and lateral planes. (c) Penile injuries are avulsion of corpus cavernosa from ischium, separation of corpus cavernosum from corpus spongiosum, corporal body fracture (d) Pelvic bone fractures. Superior inferior displacement of the prostate was measured as a distance greater than 1 cm between the prostatic apex and the inferior pubic ramis.

Anteroposterior displacement between the prostatic apex and urethral insertion in the roof of the penile bulb; and lateral displacement was measured as the distance between the prostatic apex and the bulbous urethra on the coronal image.

MR findings that support choosing the transpubic approach were (a) presence of prostatic displacement of more than 3cms, (b) length of

membranous urethral stricture > 3cms and (c) presence of extensive scar tissue around the prostatic apex.

Prostatic dislocation

The degree and direction of prostatic dislocation correlated with operative findings. Ten patients had posterior dislocation of 1 to 4 cm. The remaining patient had no dislocation in the anteroposterior direction. The prostatic apex was shifted to the right of the midline in 9 cases (1 to 3 cm) and to the left of the mid line 1 to 2 cm, the patency of the urethral lumen is not seen but the length of the prostatomembranous defect can be accurately determined by measuring the distance between the prostatic apex and the urethral insertion into the proximal corpus spongiosum.

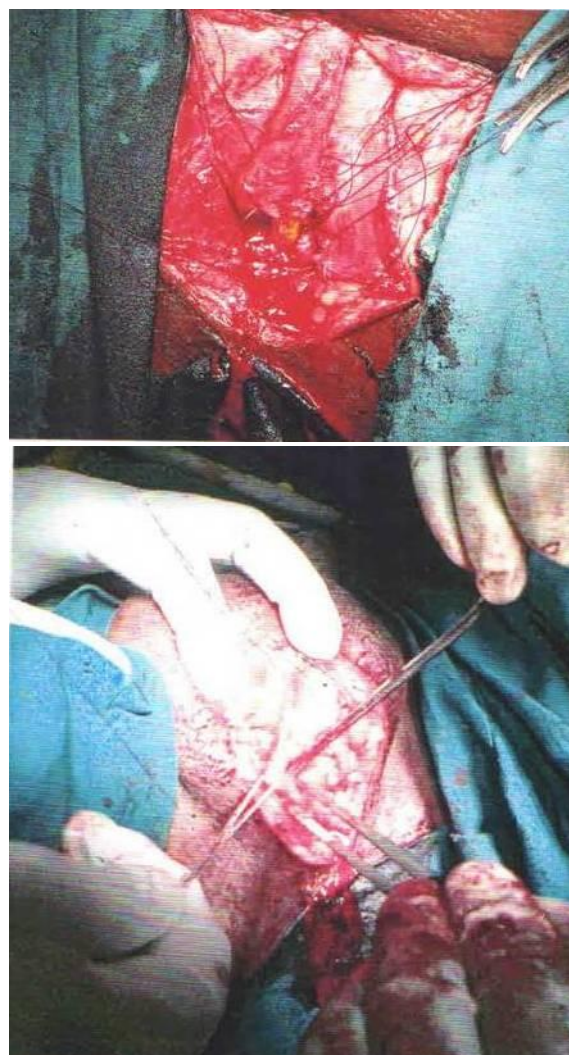
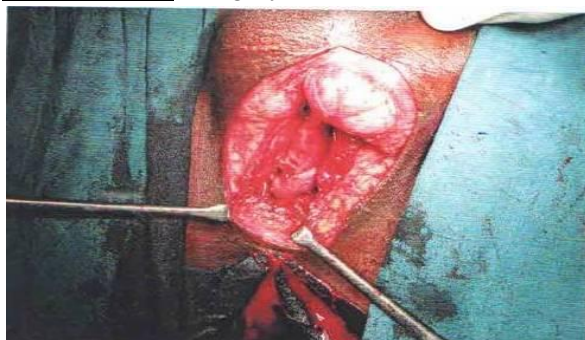
Erectile dysfunction

Out of 19 patients 2 patients had permanent impotence, this was evaluated and followed up for a period of 6 months to 28 months since the event of injury. The MRI finding in the two patients with impotence, included avulsion of the corpus cavernosum and fibrosis of the corpus cavernosum.

Surgery

We have operated 19 cases of posttraumatic posterior stricture who required definitive urethroplasty procedure. Out of 19 cases, two cases required transpubic repair, four cases required infrapubectomy along with progressive. The rest of the cases we have performed excision of the stricture, urethral mobilization and corporal separation (**Photo – 7 to 9**).

Photo – 7 to 9: Surgery.



The MRI findings helped to change the decision in initially planned surgical procedure according to conventional RGU/ MCUG. The MRI findings helped in six cases to change the decision from progressive perineal approach to infra pubectomy in four cases and transpubic repair in two cases. The fibrotic stricture segments that were excised from the patients who underwent anatomic urethroplasty were measured by using a centimeter ruler. The measurement of surgical results compared with the combined RGU/ MCUG and MRI findings. The MRI findings are correlated with surgical findings in most of the cases (**Photo – 10, 11**).

Statistical Analysis

Linear regression analysis was performed to correlate the imaging and surgical measurements of stricture length in each imaging method. The

measurement errors between the imaging and surgical values of stricture length were calculated in each imaging method and compared. A P value $<.05$ was considered to indicate a significant difference.

Photo – 10: MR Urethrography findings.

Model Summary and Parameter Estimates							
Dependent Variable: MR urethrography findings							
Equation	Model Summary					Parameter Estimates	
	R Square	F	df1	df2	Sig.	Constant	b1
Linear	.571	22.646	1	17	.000	.446	.801

The independent variable is Surgical Findings.

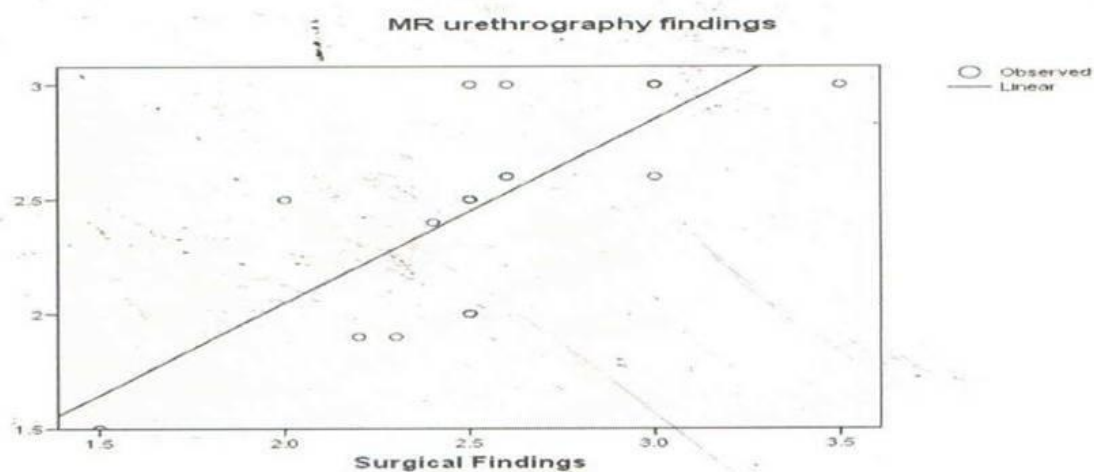
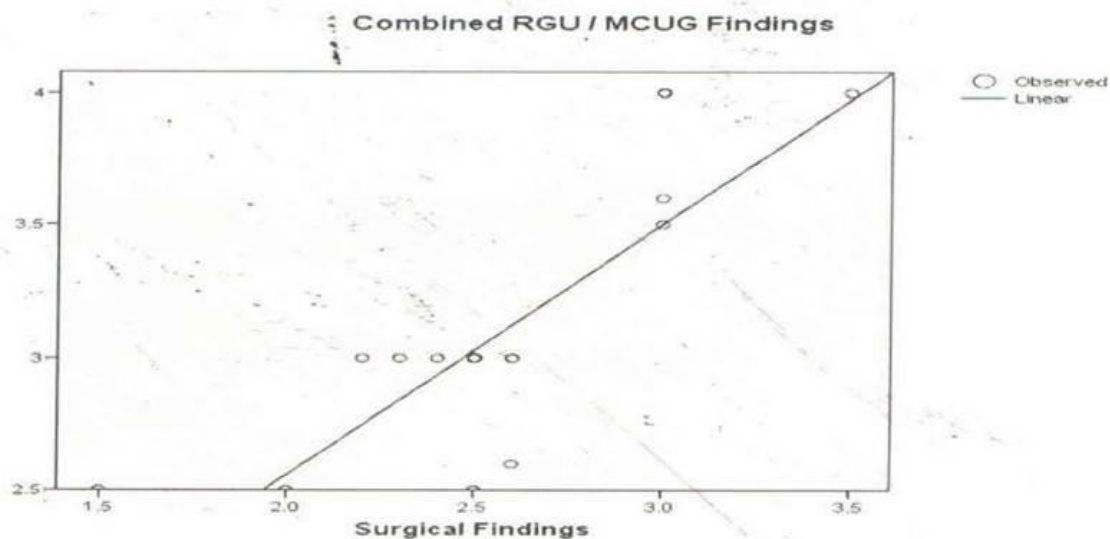


Photo – 11: Combined RGU/ MCUG findings.

Model Summary and Parameter Estimates							
Dependent Variable: Combined RGU / MCUG Findings							
Equation	Model Summary					Parameter Estimates	
	R Square	F	df1	df2	Sig.	Constant	b1
Linear	.644	30.698	1	17	.000	.673	.943

The independent variable is Surgical Findings.



Results

On the basis of the MR findings, when the stricture length (1-2.5 cm), primary anastomotic urethroplasty was performed with a perineal approach. The patients who had a long stricture (>2.5 cm) on MR images underwent progressive perineal anastomotic urethroplasty. In two cases the stricture length was more than 3.5cms we have performed through transpubic approach. The MR findings caused the urologist to change

the surgical procedure in six out of the 19 patients; the surgical procedure had previously been determined with the finding from combined RUG / MCUG. Infusion of the sterile lubricating jelly in the anterior urethra and a gentle tying of the glans sulcus with long gauze did not cause any complications, such as pain, urethral bleeding, or congestion of the glans penis, in any of the patients (**Table – 1**).

Table – 1: MR urethrography, Combined RGU/ MCUG findings and Surgical findings.

Table :

		MR urethrography findings	Combined RGU / MCUG Findings	Surgical Findings
MR urethrography findings	Pearson Correlation	1	.506(*)	.756(**)
	Sig. (2-tailed)		.027	.000
	N	19	19	19
Combined RGU / MCUG Findings	Pearson Correlation	.506(*)	1	.802(**)
	Sig. (2-tailed)	.027		.000
	N	19	19	19
Surgical Findings	Pearson Correlation	.756(**)	.802(**)	1
	Sig. (2-tailed)	.000	.000	
	N	19	19	19

* Correlation is significant at the 0.05 level (2-tailed).
 ** Correlation is significant at the 0.01 level (2-tailed).

MR Imaging Findings

In all 19 patients, the T2-weighted sagittal image demonstrated low signal intensity in the stricture segment just proximal to the distended distal urethra that was filled with the lubricating jelly. In all patients, the extent of the stricture could not be clearly delineated on the T2-weighted images of the distal urethra without the use of lubricating jelly. The intact corpora spongiosa surrounding the stricture showed strong contrast enhancement in all patients.

- The length of urethral stricture allowing for 0.5cm discrepancy in 17 of 19 patients (90%)

- The displacement of prostatic apex in 17 of 19 patients was noted (90%).
- MRI findings prompted a change in the clinically planned surgical approach in six out of 19 patients (30%).
- The MR findings correctly indicated the need for the transpubic approach in 2 of 19 patients (15%)
- Regarding surgical approach made on the basis of RGU / MCUG vs MR imaging data approached significant p value.
- The MRI findings correlated with impotence in patients having avulsion of

the corpus cavernosum with significant p value (positive predictive value) (100%).

- Both the avulsion of corpus cavernosum and superior, lateral displacements are correlated in patients with traumatic impotence (95%).

MR Urethrography Findings

On T2 weighted sagittal, coronal and axial images.

Stricture length — 1.5 to 3.5

Deviation of the prostatic apex

Superior - 3

Inferior -13

Posterior - 16

Anterior - 3

Lateral deviation - 18

Impotence -2

Corpora cavernosa avulsion -2

Discussion

There are many options for repair of posttraumatic posteriorurethral distraction defect (PUDD); the option chosen depends on several factors, the most important being stricture length. When the stricture length is 2.5cm it is generally manageable with primary anastomotic urethroplasty. Primary anastomotic urethroplasty is performed mainly with the perineal route. The transpubic approach is reserved for longer strictures and failed urethroplasties. Therefore, a careful evaluation of the posttraumatic posteriorurethral distraction defect is important in the preoperative decision-making process.

Conventional RGU combined with VCUG is the method traditionally used for the planning of a urethral reconstruction. This technique, however, often cannot provide an accurate determination of the defect length because of the poor prostatic urethral filling, and it provides little information on the extent of fibrosis of the corpora spongiosa or the prostatic displacement. Stricture length may be grossly overestimated if the bladder neck does not relax. Both the proximal and distal extents of the stricture can be demonstrated if the patient can open the bladder neck. It is rarely

possible, to demonstrate the proximal limit of the stricture because patients often have a diminished bladder capacity after months of suprapubic diversion and are unable to tolerate bladder distention sufficient to open the bladder neck voluntarily. A failure to demonstrate the prostatic urethra does not necessarily indicate a bladder neck obstruction or a stricture all the way up to the bladder neck [1-4].

To help identify the proximal limit of the stricture, a curved metal sound could be advanced through the suprapubic cystostomy track into the bladder and down through the bladder neck. The advancement of a metal sound through the bladder neck, however, can cause severe pain and hematuria from bladder neck injury. Stricture length can be underestimated if the patient is not placed in a steep oblique position for RGU. An underestimation of stricture length, as shown on the conventional RGU / MCUG image, can also occur as a result of a urinoma cavity that overlaps or is continuous with the prostatic urethra. The cavity then may be mistaken for the proximal urethral segment and be incorrectly anastomosed to the bulbar urethra.

MR imaging is likely the best imaging modality for assessing the posttraumatic pelvic anatomy and provides a noninvasive method for measuring stricture length with none of the problems associated with the conventional radiographic technique. In addition, MR imaging clearly shows the extent of the scar tissue, as well as the degree and direction of the prostatic displacement, which aids in preoperative decision making.

Yoshifumi Narumi, et al. [7] reported that the length of the urethral injury was measured correctly within 5 mm in 85% of patients by using MR imaging. Stricture length measured by Narumi et al on sagittal MR images, was not the true length of a fibrotic segment but the distance between the prostatic apex and the bulb of the penis.

Therefore, we used sterile lubricating jelly to distend the urethra distal to the stricture and delineate the distal limit of the stricture. Results in our study showed that MR urethrography demonstrated a significantly lower error in the measurement of stricture length than did combined RGU / MCUG and was useful for selecting the most appropriate surgical procedure.

After 3 months of urethral injury, the scar tissue at the urethral disruption site is stable and mature, which indicates that a reconstructive procedure can be undertaken safely if the associated injuries have been stabilized. Contrast medium is injected to evaluate the degree of activity in the inflammatory lesions at MR imaging with T1 sequences, and contrast enhancement has been shown to correlate with the presence of active inflammation.

We have compared our study results with the literature available.

Yoshifumi Narumi, et al. [7], performed the MR imaging study in 27 patients who requiring definitive urethroplasty procedure. The study results revealed the length of urethral stricture in 23 out of 27 patients (85%) and displacement of the prostatic apex in 19 of 21 (90%) are correlated with the surgical findings. The study revealed with a significant p value (1993).

Christopher M. Dixon, et al. [8], A total number of 18 patients underwent MRI imaging before open urethroplasty, the surgical results are correlated with the MRI findings with a significant p value (1992).

Deuk Jae Sung, et al. [5], 12 patients with obliterative stricture underwent MR imaging before surgery, the mean measurement error at MR imaging (mean, 0.31 cms) was significantly lower ($P < 0.05$) than the findings of conventional.

RUG/ MCUG (mean, 1.69cm). Linear regression analysis showed a stronger linear relationship

between the MR and the surgical measurements ($P < 0.001$) (2005).

Yasser Osman, et al. [6] studied a 20 men who are requiring surgery for urethral stricture, the accuracy of MR urethrography regarding diagnosis is more than 85%. The MR findings are correlated with surgical findings in most of the cases with a significant p value (2006).

Nurenberg P, et al. [10], the study was conducted with MR imaging in 18 patients who are requiring definitive urethroplasty. The MR findings are correlated with surgical findings in most of the cases with a significant p value (1997).

Noel A Armenakas, et al. [9], in 15 patients of prostatomembranous stricture MRI imaging was performed before surgery. The MR findings are correlated with surgical findings in most of the cases with a significant p value (1993).

This study gives an idea with the experience of others in regard to the degree of dislocation in patients with PUDD with sagittal, coronal views of MRI reconstruction.

Conclusion

Our study demonstrated that MR urethrography reveals a significantly lower error in the measurement of stricture length than did combined RGU / VCUG. The advantage of MR imaging are non invasive multiplanar modality without any radiation. MR urethrography could accurately measure the stricture length in T2 sagittal, coronal views of reconstruction. It also judges the extent of spowiofibrosis, prostatic apex dislocation, which will aid the surgeon to perform appropriate surgical procedure. The conventional RGU / MCUG is unable to appropriate surgical procedure. The conventional RGU / MCUG is unable to provide these details accurately. It is useful for selecting the most appropriate surgical procedure in patients with posterior urethral distraction defects. When compare to combined RGU / MCUG the MR

Urethrography is more accurate in estimating the length of posterior urethral distraction defects. In conclusion the number of cases in our study are less, but they are comparable with the literature available. The MR urethrography is helpful in designing the most appropriate surgical approach preoperatively.

References

1. Wein AJ, et al. Campbell and Walsh. Text book of Urology, 9th edition, Saunders (W.B.) Co. Ltd., 2006.
2. Smith General Urology, 16th edition, Appleton and Lange, 2003.
3. Davidson. Radiological Principles, 3rd edition, Churchill Livingstone.
4. Mc Annich JW. Traumatic and Reconstructive Urology, 1996.
5. Deuk Jae Sung, et al. Obliterative Urethral Stricture: MR Urethrography versus conventional Retrograde Urethrography with voiding Cystourethrography. Radiology, 2006; 240(3): 1-14.
6. Yasser Osman, et al. Magnetic Resonance Urethrography in Comparison to Retrograde Urethrography in Diagnosis of Male Urethral Stricture: Is it Clinically Relevant? European Urology, 2006; 50: 587 - 594.
7. Yoshifumi Naruni, et al. MR Imaging of Traumatic Posterior Urethral Injury. Radlogy, 1993; 188: 439-443.
8. Christopher M., Dixon Jack W, McAnnich, et al. Magnetic Resonance Imaging of Traumatic Posterior Urethral Defects and Pelvic Crush Injuries. The Jr. of Urology, 1992; 148: 1162-1165.
9. Noel A. Armenakas, Jack W. McAnninch, et al. Posttraumatic impotence Magnetic Resonance Imaging and Duplex Ultrasound in diagnosis and Management. Jr of Urology, 1993; 149: 1272 - 1275.
10. Nurenberg P., Zimmern P.E. Role of MR Imaging with Transrectal Coil in the Evaluation of Complex Urethral Abnormalities. American Jr of Radiology, 1997; 169: 1335 – 1338.