

Original Research Article


Anastomotic esophageal strictures in children with post-surgical correction of tracheo-esophageal fistula (TEF): Our experience with endoscopic dilatation – A tertiary care center study

M. Umadevi^{1*}, Swapnika Gadde², Abhinay Rajarao², Abdul Samad Peshimam², P. Shravan Kumar³

¹Associate Professor, ²Post Graduates, ³Professor and Head

Department of Gastroenterology, Gandhi Medical College, Secunderabad, Telangana, India

*Corresponding author email: umadevimalladi_66@yahoo.co.in

	International Archives of Integrated Medicine, Vol. 7, Issue 10, October, 2020.	
	Available online at http://iaimjournal.com/	
	ISSN: 2394-0026 (P)	ISSN: 2394-0034 (O)
	Received on: 12-09-2020	Accepted on: 23-09-2020
	Source of support: Nil	Conflict of interest: None declared.
How to cite this article: M. Umadevi, Swapnika Gadde, Abhinay Rajarao, Abdul Samad Peshimam, P. Shravan Kumar. Anastomotic esophageal strictures in children with post-surgical correction of tracheo-esophageal fistula (TEF): Our experience with endoscopic dilatation – A tertiary care center study. IAIM, 2020; 7(10): 95-99.		

Abstract

Background: Improved surgical techniques, as well as pre and postoperative care, have dramatically changed survival of children with esophageal atresia (EA) with trachea-esophageal fistula (TEF) over last decades. The increase in survival caused a number of young children with post-operative esophageal strictures referred for endoscopic management.

Objective: To assess efficacy and safety of endoscopic dilatation of anastomotic strictures in patients with post-surgical repair of EA and TEF.

Materials and methods: We retrospectively analyzed clinical endoscopic data of 52 patients with post-surgical anastomotic strictures from March 1994 to December 2019. All procedures were performed under local anesthesia with use of fluoroscopic guidance. Outcome parameters measured included the location of stricture, number of dilations, procedural success rates, and complications such as esophageal perforation.

Results: Of 52 patients analyzed, 16 (31%) underwent dilatation with SG dilators used in initial part of the study i.e., from 1994 to 2004. With the availability of CRE balloons, further patients were

dilated with CRE balloon 36/52 (69%). Strictures were located centrally in 46 patients (88.6%) and eccentrically in 6 patients (11.5%). Associated pseudodiverticula above the stricture noted in 14(26.9%). The number of dilatations varied from 2 to 16 sessions, mean being 6.3 sessions. Complications secondary to procedure were observed in 7 patients with fever in 4 (7.6%), minor bleed in 2(3.8%) and perforation in one (1.9%) and were treated conservatively. We have not encountered any mortality. No significant difference between SG dilators and CRE balloon group.

Conclusions: Endoscopic dilatation of post-surgical esophageal strictures in patients with EA and TEF with SG dilators CRE balloon dilatation is safe and effective with less number of complications. Endoscopic dilatation under local lignocaine anesthesia is feasible, effective and safe.

Key words

Esophageal atresia, Tracheo-esophageal fistula, Anastomotic esophageal stricture, Endoscopic dilatation, CRE Balloon.

Introduction

Esophageal atresia (EA) is one of the most common congenital anomaly of esophagus, often associated with trachea-esophageal fistula (TEF) with overall incidence ranging from 1 in every 2500 to 4500 live births [1]. The primary treatment of EA with or without TEF is surgery. First successful repair is performed in 1941 by Dr Cameron Height. The survival rate has improved dramatically with new surgical techniques, as well as pre and postoperative care with reports of survival as high as 95% in specialized centers [2]. However, anastomotic complications are frequent and remain important cause of post-operative morbidity [3]. The reported incidence of anastomotic stricture after EA repair has varied in case series from as low as 9% to as high as 80% [4].

The cornerstone of esophageal stricture treatment is endoscopic-assisted esophageal dilatation using a bougie dilator or balloon catheter. The most frequently used dilators are Savery Gilliard (SG) dilators and CRE (controlled radial expansion) balloons. The goal of esophageal dilation is to increase the luminal diameter of the esophagus while also improving dysphagia symptoms. Dilatations over 2 weeks to 2 months are undertaken before labeling the strictures as refractory.

Materials and methods

We had analyzed retrospectively all children who underwent endoscopic dilatation for anastomotic stricture post EA/TEF repair over a period of 25 years from May 1994 to December 2019 in Department of Gastroenterology, Osmania General Hospital and Gandhi Hospital in Hyderabad. All patients were referred from Niloufer Children Hospital, Hyderabad. Initial assessment consists of, detailed clinical history and examination was done. Contrast enhanced radiological examination of esophagus was done in all patients. Nutritional status and BMI was noted in all patients. Parents were informed of the possible complications, need for hospitalization, efficacy of treatment offered and Informed consent was obtained in all cases.

Endoscopic procedures were performed under lignocaine topical anesthesia with airway protection and a minimum fasting period of 6 hours. On endoscopy, the location, diameter and morphological aspects of the stricture were assessed to facilitate the most appropriate dilator use. The guide wire was inserted under endoscopic control under fluoroscopy. Dilatation sessions were repeated at an average interval of 2 weeks with the use of maximum 3 dilators with progressively increasing diameters per session. After the procedure, all children were kept NBM for 6 hours and treated with antibiotics and sucralfate, proton pump Inhibitors for 5 days. Patients were remained under observation for overnight and discharged next day. Relief of

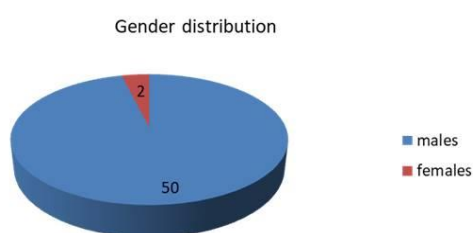
dysphagia, improvement of nutrition and weight gain during the follow up were used as clinical parameters to determine the response to endoscopic treatment as well as the interval between the sessions. The ideal final diameter of the esophageal lumen was based on patient's symptoms, feeding difficulties and nutritional status. Patients were followed biannually on outpatient basis for a period of 2 years to 3 years post completion of dilatation

The following dilators were used: SG dilators (6 mm to 12 mm), CRE balloon (6 mm to 12 mm) and were chosen according to the endoscopic, radiologic characteristics of the stricture.

Results

A total of 72 children under went endoscopic dilatation between 1994 and 2019, however only 52 patients' data analyzed for lack of follow up. A total 52 child aged between 6 months and 1½ years at the time of initial presentation were assessed. Of these 52 patients 50 were males and two were females (**Figure - 1**).

Figure - 1: Gender distribution in the study population.



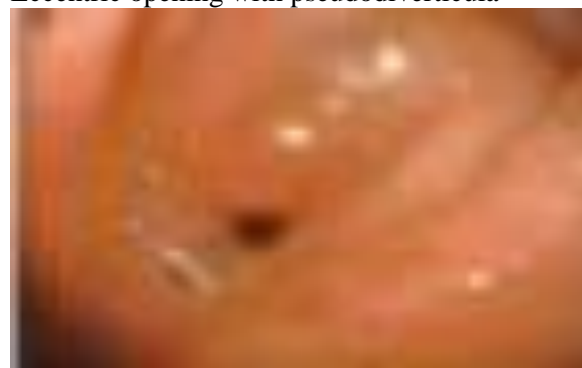They were subjected to total number of 326 dilatations with a range of 2- 16 sessions per patient. In 31% (16/52), SG dilators used in initial part of the study i.e., from 1994 to 2019. With the availability of CRE Balloons (Boston scientific microvasive) further stricture dilatation done with CRE balloons from 2004 onwards in 69% (32/52).

When morphology of strictures were analyzed, stricture opening is located centrally in majority of patients 46 (88.5%) and was eccentric in 6

(11.5%) patients (**Figure - 2**). Associated pseudodiverticula above the stricture noted in 12(23%) patients with single diverticula in 9 and Multiple in 3 patients.

Figure - 2: Endoscopic Morphological appearances.

Eccentric opening with pseudodiverticula



Central opening



Complications secondary to procedure were observed in 7 (13.4%) patients, with fever in 3(5.7%), minor bleed in 6 (4 in SG group and 2 In CRE group) and one had perforation after SG dilatation and treated conservatively. We have encountered neither mortality nor refractory strictures requiring surgery.

Efficacy: The number of dilatations varied from 2 to 16 sessions, mean being 6.3. We did not observe any relation between time gap between surgery and commencement of dilatation schedules.

On follow up: Post procedure lower respiratory tract infections were seen in 18 patients (34.6%), food impaction noted in 8(15.4%) patients

(Table - 1). Common food impactions that were noted were fruit seeds in 4, one had ground nut, 3 had moong dal and another had large curry leaf indicating the necessity of counseling parents in food care. All were removed successfully under lignocaine anesthesia. Lower respiratory tract infections responded to oral antibiotics and 3 (5.7%) required hospitalization.

Table - 1: Complications on post procedural follow up.

Complications	SG group (n-16)	CRE balloon (n-36)
FB impaction	2	6
Minor Respiratory infections	6	9
Pneumonia requiring Hospitalization	2	1
Post procedure perforation	1	0

Discussion

The incidence of esophageal strictures in pediatric population varies with the geographic regions and endoscopy referral centers. The increase in survival of infants with EA/ TEF with resultant successful surgery and availability of well-equipped neonatal intensive care units and personnel had increased referral to endoscopic dilatation for anastomotic strictures following surgical correction. Better response to endoscopic treatment requiring few dilatation sessions for an appropriate lumen diameter have been noticed and majority become asymptomatic after 5 years of age.

In our study out of 52 patients 50 were males and two were female children. EA is more common in boys than girls, which may have influenced our finding of a higher rate of esophageal stricture in males [5]. Congenital anomalies were associated in 68% of patients with EA [6]. We had not seen any congenital anomalies in the post-operative children. In patients with eccentric lumen, pseudo diverticulae and distorted

anatomy there is technical problem with guide wire placement, in such patients the ideal final diameter of esophageal lumen is determined by the patient's clinical condition like improvement of dysphagia, nutritional status and weight gain [7]; in our cases it was 12 mm.

We had post procedure minor complications in 13.3% of patients where as 4.8% in Bittencourt, et al. [8]. Perforation is considered as one of the most dreaded complications of dilatation especially in children with considerable morbidity [9], however, in our study perforation occurred in one and it is managed conservatively. In a study done in Taiwan 14 of 16 (87.5%) patients with post-surgical stricture have diagnosed with reflux esophagitis after undergoing esophageal dilatation [10], however, we have encountered none in our study ,may be due to short period of follow up of 3 years

Conclusion

Endoscopic dilatation of anastomotic esophageal strictures after surgical correction is safe, effective with good success rate under lignocaine topical anesthesia. With the advent of CRE balloon dilatation the success rate is high with few complications. Patients should be monitored regularly, even after achieving adequate esophageal lumen. Proper nutritional care and preparation of feeds plays a very important role to avoid food impaction. We want to stress the point that all these dilatations are done under topical anesthesia, and we have not encountered refractory strictures requiring surgery.

References

1. Krishnan U, Mousa H, Dall'Oglio L, Homaira N, Rosen R, Faure C, et al. ESPGHAN-NASPGHAN Guidelines for the Evaluation and Treatment of Gastrointestinal and Nutritional Complications in Children With Esophageal Atresia-Tracheoesophageal Fistula. *J Pediatr Gastroenterol Nutr.*, 2016; 63(5): 550-570.

M. Umadevi, Swapnika Gadde, Abhinay Rajarao, Abdul Samad Peshimam, P. Shravan Kumar. Anastomotic esophageal strictures in children with post-surgical correction of tracheo-esophageal fistula (TEF): Our experience with endoscopic dilatation – A tertiary care center study. *IAIM*, 2020; 7(10): 95-99.

2. Chittmitrapap S, Spitz L, Kiely EM, Brereton RJ. Anastomotic stricture following repair of Esophageal Atresia. *J Pediatr surg.*, 1990; 25(5): 508-11.
3. Yanchar NL, Gordon R, Cooper M, Dunlap H, Soucy P. Significance of the clinical course and early upper gastrointestinal studies in predicting complications associated with repair of esophageal atresia. *Journal of pediatric surgery*, 2001; 36(5): 815-22.
4. Banjar HH, Al-Nassar SI. Gastroesophageal reflux following repair of esophageal atresia and tracheoesophageal fistula. *Saudi Med J.*, 2005; 26(5): 781-5.
5. Ekselius J, Salö M, Arnbjörnsson E, Stenström P. Treatment and Outcome for Children with Esophageal Atresia from a Gender Perspective. *Surgery research and practice*, 2017; 2017: 8345798.
6. Harmon CM, Coran AG. Congenital anomalies of the esophagus in children: *Pediatric surgery*. Philadelphia: Mosby Elsevier; 2006, p. 1051–81.
7. Güitrón A, Adalid R, Nares J, Mena G, Gutierrez JA, Olivares C, et al. Benign esophageal strictures in toddlers and pre-school children. Results of endoscopic dilation. *Rev Gastroenterol Mex.*, 1999; 64(1): 12.
8. Bitten court PF, Carvalho SD, Ferreira AR, Melo SF, Andrade DO, Figueiro Filho PP, et al. Endoscopic dilatation of esophageal strictures in children and adolescents. *J pediatric (Rio J)*, 2006; 82: 127-31.
9. Martinezl, Rivas S, Hernandez F, Avila LF, Murcia J, et al. Aggressive conservative management of Esophageal perforations in children. *J pediatric surg.*, 2003; 38: 685-689.
10. Chiang CM, Hsu WM, Chang MH, Hsu HY, Ni YH, Chen HL, Wu JF. Risk factors and management for anastomotic stricture after surgical reconstruction of esophageal atresia. *Journal of the Formosan Medical Association*, 2020 Jun 22.