

Case Report


Breast Carcinoma in a 62 year old male: A case report

G.V. Manoharan^{1*}, Maharaja P²

¹ Professor, ² Assistant Professor,

Department of General Surgery, Sri Manakula Vinayakar Medical College and Hospital, Pondicherry, India

*Corresponding author email: gvmfhm@yahoo.co.in

	International Archives of Integrated Medicine, Vol. 7, Issue 11, November, 2020.	
	Available online at http://iaimjournal.com/	
	ISSN: 2394-0026 (P)	ISSN: 2394-0034 (O)
	Received on: 08-10-2020	Accepted on: 18-10-2020
	Source of support: Nil	Conflict of interest: None declared.
How to cite this article: G.V. Manohara, Maharaja P. Breast Carcinoma in a 62 year old male: A case report. IAIM, 2020; 7(11): 56-58.		

Abstract

Breast cancer in men is a rare entity. It represents about 0.2% of all cancers, and about 1% of all breast cancers. Presentation is usually a lump or nipple inversion, but is often late, with more than 40% of individuals having stage III or IV disease. Risk factors for MBC are poorly understood and include working in high-ambient temperatures and exhaust fume exposure. MBC is associated with hyperoestrogenic states found in liver disease, Klinefelter's syndrome, gonadal dysfunction or obesity. We describe a case of breast cancer in a 62 year old man who presented with advanced disease.

Key words

Breast carcinoma, Male, Clinical presentation, Diagnostic and therapeutic modalities.

Introduction

Male breast cancer is a rare disease which accounts for about 1% of all breast cancers. Most of studies in breast cancer have been conducted in women and few large studies have been done in men due to the low prevalence [1]. The risk factors for male breast cancer include working at high temperatures and exposure to exhaust fumes. It has an association with hyperestrogenic states like liver disease, Klinefelters syndrome, gonadal dysfunction etc. Presentation is usually a lump or nipple inversion, but is often late, with

more than 40% of individuals having stage III or IV disease. Most tumors are ductal and 10% are ductal carcinoma in situ. Surgery is usually mastectomy with axillary clearance or sentinel node biopsy. Indications for radiotherapy, by stage, are similar to female breast cancer [2]. Because 90% of tumors are oestrogen-receptor-positive, tamoxifen is standard adjuvant therapy, but some individuals could also benefit from chemotherapy. Hormonal therapy is the main treatment for metastatic disease, but chemotherapy can also provide palliation. The age frequency distribution in women with breast

cancer is bimodal with peaks at 52 and 71 years, whereas in men it is unimodal with a peak at age 71 years [3]. Male breast cancer behaves in a similar way to postmenopausal breast cancer in women. Delay in diagnosis can result from ignorance of the existence of breast cancer among men. This adversely affects prognosis, with little improvement over the past 25 years [4].

Case report

A 62 year old man presented to the OPD with a fungating mass in the right breast for the past 6 months, the mass was associated with pain for the past 2 weeks. He had history of lump in the right breast for the past 9 months. On examination, the mass was 5x4 cm with involvement of the right axillary lymph nodes. Core needle biopsy of the mass was done and reported as infiltrating ductal carcinoma with ER, PR positive and HER2 negative. Patient had a metastatic screening done with a CT chest and abdomen which was negative for liver and lung involvement. Patient underwent a modified radical mastectomy. After resection there was a raw area of size 12x5cm which was covered with a skin graft from the Left thigh. Post-surgery patient was discharged and started on chemotherapy. 1 cycle of Adriamycin with cyclophosphamide, 3 cycles of 5 Fluorouracil, Epirubicin and cyclophosphamide and 5 cycles of paclitaxel were given.

Patient reported 3 months after the last cycle of chemotherapy with a mass in the Right axilla. A diagnosis of recurrent breast carcinoma in the axilla was made and repeat right axillary nodal dissection was carried out. A 10x10 cm mass was found intraoperatively which was found infiltrating the axillary vein, pectoralis minor muscle, serratus anterior muscle and the nerve to latissimus dorsi. An accessory axillary vein was found (**Figure - 1**) and hence the tumor was removed by ligating axillary vein which it was infiltrating. Biopsy showed adequate tumor margin clearance. Post procedure patient was

started on hormone therapy with tamoxifen and is being planned for radiotherapy (**Figure - 2**).

Figure – 1: showing axillary vein with accessory axillary vein.

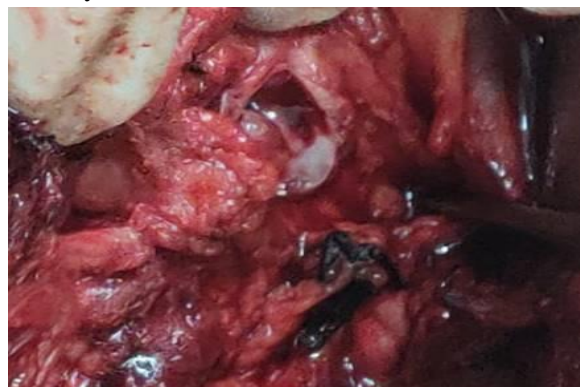
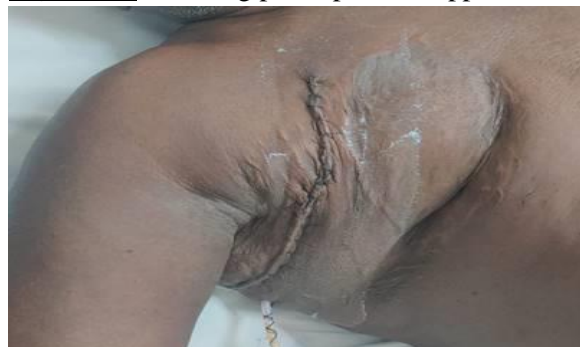
Figure – 2: showing post-operative appearance.



Discussion

Invasive ductal carcinoma in men has a unique presentation. Nearly half of breast cancer cases in men are diagnosed in a late stage, probably due to delay in seeking medical attention. Skin involvement occurs earlier in men. Treatment strategies for male breast are extrapolated from data in women. Men with breast carcinoma have a poor prognosis due to their late stage of presentation [5].

There is a close relation between the BRCA2 gene mutation and male breast cancer. It has also been observed, however, that some cases involve BRCA1 participation. Other conditions that have been associated with the occurrence of breast neoplasms in men are cirrhosis, testicular trauma, obesity, radiation therapy exposure, and the use of exogenous estrogen. Family history of breast cancer and genetic conditions such as

Klinefelter's syndrome and Cowden's disease has association with breast cancer in men [6].

Estrogen receptors and progesterone receptors are present in about 90% and 81% of breast cancers in males, respectively. Overexpression of HER-2 heralds a worse prognosis [7].

Similar to breast cancer cases in women, earlier detection of male breast cancer is associated with better outcomes. Although males have considerably less mammary tissue than women, the workup must include a clinical exam, mammography, and percutaneous biopsies. The core needle biopsy is important because it enables a definitive diagnosis of invasive breast cancer and evaluation of hormonal receptor status and Her2 overexpression [8].

Tamoxifen is considered as the optimal adjuvant therapy option for male patients with hormone receptor positive disease. Some studies have demonstrated an improved disease-free and overall survival compared with historical controls using adjuvant anthracycline-based therapies [9].

Overall survival of male breast cancer is similar to that of women with breast cancer. Similar to women with breast cancer, stage, tumor sized, and axillary lymph node status are important factors influencing outcome. The impression that male breast cancer has a worse prognosis may stem from the tendency toward diagnosis at a later stage [10].

Conclusion

Breast carcinoma in men is extremely rare; the peak incidence is around the seventh decade of life. Risk factors include genetic factors and hormonal abnormalities. Delay in seeking medical attention leads to worse prognosis in men. Early diagnosis and treatment leads to similar outcomes as compared to women with breast cancer. Creating awareness both among patients and treating physicians holds the most promise in improving outcomes in these patients.

References

1. Yalaza M, İnan A, Bozer M. Male Breast Cancer. *J Breast Health*, 2016; 12(1): 1-8.
2. Sanguinetti A, Polistena A, Lucchini R, et al. Male breast cancer, clinical presentation, diagnosis and treatment: Twenty years of experience in our Breast Unit. *Int J Surg Case Rep.*, 2016; 20S(Suppl): 8-11.
3. Fentiman I. Male breast cancer: a review. *Ecancermedicalscience.*, 2009; 3: 140.
4. Rudlowski C. Male Breast Cancer. *Breast Care (Basel).*, 2008; 3(3): 183-189.
5. Madeira M, Mattar A, Passos RJ, et al. A case report of male breast cancer in a very young patient: what is changing?. *World J Surg Oncol.*, 2011; 9: 16.
6. Misra SP, Misra V, Dwivedi M. Cancer of the breast in a male cirrhotic: is there an association between the two? *Am J Gastroenterol.*, 1996; 91: 380-382.
7. Hill A, Yagmur Y, Tran KN, Bolton JS, Robson M, Borgen PI. Localized male breast carcinoma and family history. An analysis of 142 patients. *Cancer*, 1999; 86(5): 821-5.
8. Scott-Conner CE, Jochimsen PR, Menck HR, Winchester DJ. An analysis of male and female breast cancer treatment and survival amongst demographically identical pairs of patients. *Surgery*, 1999; 126(4): 275-80.
9. Auvinen A, Curtis RE, Ron E. Risk of subsequent cancer following breast cancer in men. *J Natl Cancer Inst.*, 2002; 94: 1330-1332.
10. Park S-Y, Cho YU, Kim SJ, Hur MH. A case report of 29-year-old male patient with breast carcinoma. *Korean Journal of Clinical Oncology*, 2017; 13(1): 50-53.